



Endoscopic Treatment of Middle Ear Myoclonus with Stapedius and Tensor Tympani Section: A New Minimally-Invasive Approach

Natasha Pollak^{1*}, Roya Azadarmaki² and Sidrah Ahmad¹

¹Department of Otolaryngology–Head and Neck Surgery, Temple University School of Medicine, Philadelphia, Pennsylvania, USA.

²Metropolitan NeuroEar Group, Rockville, Maryland, USA.

Authors' contributions

This work was carried out in collaboration between all authors. Author NP designed study, performed surgery, literature review, writing, reviewing. Author RA literature review, writing, reviewing. Author SA performed surgery, writing, reviewing. All authors read and approved the final manuscript.

Case Study

Received 26th January 2014
Accepted 11th March 2014
Published 27th March 2014

ABSTRACT

Aims: We describe a new, entirely endoscopic surgical technique for treatment of middle ear myoclonus.

Case Presentation: In our patient, the stapedius and tensor tympani tendons were sectioned to control chronic middle ear myoclonus. The procedure was performed using endoscopic ear surgery techniques, with the aid of rigid Hopkins rod endoscopes. Control of the pulsatile tinnitus was achieved after endoscopic tenotomy of the stapedius and tensor tympani, without any complications.

Discussion and Conclusion: Endoscopic tensor tympani and stapedius tendon section is a new, minimally invasive treatment option for middle ear myoclonus that should be considered as a first line surgical approach in patients who fail medical therapy. The use of an endoscopic approach allows for easier access and vastly superior visualization of the relevant anatomy, which in turn allows the surgeon to minimize dissection of healthy tissue for exposure. The entire operation, including raising the tympanomeatal flap and tendon section can be safely completed under visualization with a rigid endoscope with good control of the pulsatile tinnitus.

*Corresponding author: Email: pollakn1@hotmail.com;

Keywords: *Middle ear myoclonus; stapedius myoclonus; tensor tympani myoclonus; pulsatile tinnitus; endoscopic ear surgery; functional endoscopic ear surgery; minimally-invasive surgery.*

1. INTRODUCTION

Middle ear myoclonus is an uncommon but well-known cause of pulsatile tinnitus. [1,2] It was first described by Adam Politzer in the late 19th century and is still not a fully understood clinical entity. The quality of tinnitus associated with this condition is variable and described by patients as crackling, clicking, buzzing, throbbing, tapping, thumping, blowing, pulsations, fluttering moth, machinery rumble and whooshing sounds. [2,3] When myoclonus is slower, individual clicks can be discerned, once the pace of muscle contraction is faster, the sound blends into one continuous tone. Sometimes middle ear myoclonus is described as a sound slowly escalating in loudness over several minutes, only to stop abruptly. The cycle may repeat and these slowly waxing and abruptly stopping episodes may occur frequently throughout the course of the day. The possible etiology of tinnitus include sound produced by stapedius muscle or tensor tympani muscle contractions, movement of the tympanic membrane resulting from muscle contractions and cochlear response to a pressure wave produced from movement of the ossicular chain [4].

Middle ear myoclonus has been at times diagnosed as an isolated clinical entity or in association with acoustic trauma, hemifacial spasm, blepharospasm or essential palatal tremor (palatal myoclonus) [2]. Literature reports on this disease entity have been mostly in the form of case reports and case series. The largest case series to date reports one institution's experience with 58 patients [5]. Stressful events and noise exposure were reported as the most common triggers of middle ear myoclonus in this relatively large case series.

There is not a clear algorithm for the management of middle ear myoclonus, mostly because it is an infrequently encountered condition that is not fully understood. Conservative therapeutic strategies that have been used in recent years include reassurance, psychotherapy, anti-convulsants, muscle relaxants, tinnitus masking devices and zygomatic pressure maneuvers [1,4,5,6-9]. Treatment with botulinum toxin (Botox) [10] and tensor tympani and stapedius tenotomies are non-conservative therapies.

Surgical management for middle ear myoclonus involves tensor tympani tenotomy, stapedius tenotomy, or both and has been largely successful [1,3-5,11]. We report the first case of endoscopic surgical treatment of middle ear myoclonus.

Hidaka et al. [3] reported that a history of facial palsy, presence of provoking factors and confirmation of muscle contraction leading to tinnitus during surgery, are significant factors leading to selective tenotomy. In their meta-analysis of 24 patients surgically treated for middle ear myoclonus, patients with subjective tinnitus had a higher rate of selective stapedius tenotomy. They did not find palatal myoclonus or tympanic membrane movement with tinnitus as significant factors leading to selective tenotomy. In 1981, Klochoff [12] first described the "tensor tympani syndrome" which includes slow changes in middle ear impedance measurements described as "tonic tensor phenomenon" and is a psychosomatic syndrome associated with high levels of anxiety and stress.

Transcanal microscopic approach to stapedius tenotomy involves raising a tympanomeatal flap, curetting the scutum for exposure in most cases, followed by transection of the

stapedius tendon. Visualization of the tensor tympani tendon however is more challenging due to its relatively inaccessible location. Different approaches are reported for adequate exposure and transection of the tensor tympani tendon using the transcanal microscopic approach [13,14]. Blindly sliding a knife between the long processes of the incus and malleus handle to cut the tendon after raising a traditional flap is one approach that can be suboptimal as the entire tendon may not be in view. Alternative approaches include extending the tympanomeatal flap superiorly and anteriorly with elevation of the drum off the malleus handle for better exposure [13] or approaching the tendon through an anterior tympanomeatal flap [14].

2. PRESENTATION OF CASE

A 66 year-old man presented to the Otolaryngology clinic with a 10-year history of right-sided intermittent pulsatile tinnitus. The tinnitus was describes as a slowly escalating crackling sound which stops abruptly. These episodes occur several times per day. He was previously diagnosed with middle ear myoclonus by a neurologist who treated him with carbamazepine with partial relief for years. During the past few months, pulsatile tinnitus worsened in both severity and frequency of episodes despite the carbamazepine. MRI scan of the brain revealed no lesions in the Guillain Mollaret triangle or any other lesion that could be the cause of pulsatile tinnitus. Patient elected to undergo surgery for definitive treatment of the tinnitus.

Endoscopic treatment of middle ear myoclonus was done under general anesthesia in the same-day surgery setting. If the exact cause of the middle ear myoclonus is known, only the responsible muscle tendon is severed, otherwise in most cases, both the stapedius and tensor tympani tendons are severed. The patient was placed supine in the usual "otologic" surgical position, with the upper body slightly elevated and head turned gently to the contralateral side. The head of the bed is not usually turned but faces the anesthesiologist. Use of a facial nerve monitor is not necessary in routine cases. The patient is prepped and draped in the usual sterile manner for ear surgery. The instruments commonly found on a tympanoplasty/stapedectomy tray are used. Rigid Hopkins rod endoscopes are used for visualization. In this case, we used the 4.0 mm and 2.7 mm diameter, zero and 30° endoscopes commonly used for endoscopic sinus surgery. Acceptable endoscopes are rigid Hopkins rods, 2.5–4.0 mm diameter, straight and 30° angled, mid length. These are essentially the adult and pediatric sinusscopes that are commonly found in operating suites where endoscopic sinus surgery is performed. The endoscope is connected to a high-definition 3-CCD (3-chip) camera. The surgeon is seated in the usual manner and the video screen is positioned directly opposite the surgeon. The scrub nurse also usually prefers to sit opposite the surgeon, in a place with a good view of the video screen, with a Mayo stand ready with commonly used instruments for easy access. The sponge containing the defog solution is affixed the patient's temple area, not over the eye. The surgeon holds the endoscope in his or her non-dominant hand and instruments the ear with the dominant hand [15].

The external auditory canal is examined using the endoscope and cleansed of debris. Next, canal injections containing epinephrine need to be made circumferentially for hemostasis. This can be done under endoscopic or microscopic guidance, depending on the skill and comfort of the surgeon. A stapes-style posterior canal incision is made and the tympanomeatal flap elevated under endoscopic vision. An ear speculum is not necessary. The annulus is elevated and middle ear space entered. A small cottonoid soaked in epinephrine solution may help with hemostasis as the tympanomeatal flap is elevated using

this one-handed technique. The tympanomeatal flap is elevated to the level of the malleus. There is no need to elevate the flap off the malleus handle or raise an anterior tympanomeatal flap. By positioning the endoscope tip near the bony tympanic ring, both the stapedius tendon and tensor tympani tendon can be readily seen. The stapedius tendon originates from the pyramidal eminence in the posterior mesotympanum and attaches to the stapes capitulum. The tensor tympani courses in a semicanal paralleling the Eustachian tube, continues along the floor of the tympanic cavity, paralleling the tympanic segment of the facial nerve, then turns 90° and emerges from the cochleariform process, attaching to the underside of the malleus neck and manubrium. There is no need to curette the scutum or posterior bony wall for exposure. These maneuvers can injure the chorda tympani. If the chorda tympani is not injured during flap elevation, it can easily be preserved. The procedure is documented by recording video or still photographs Fig. 1.

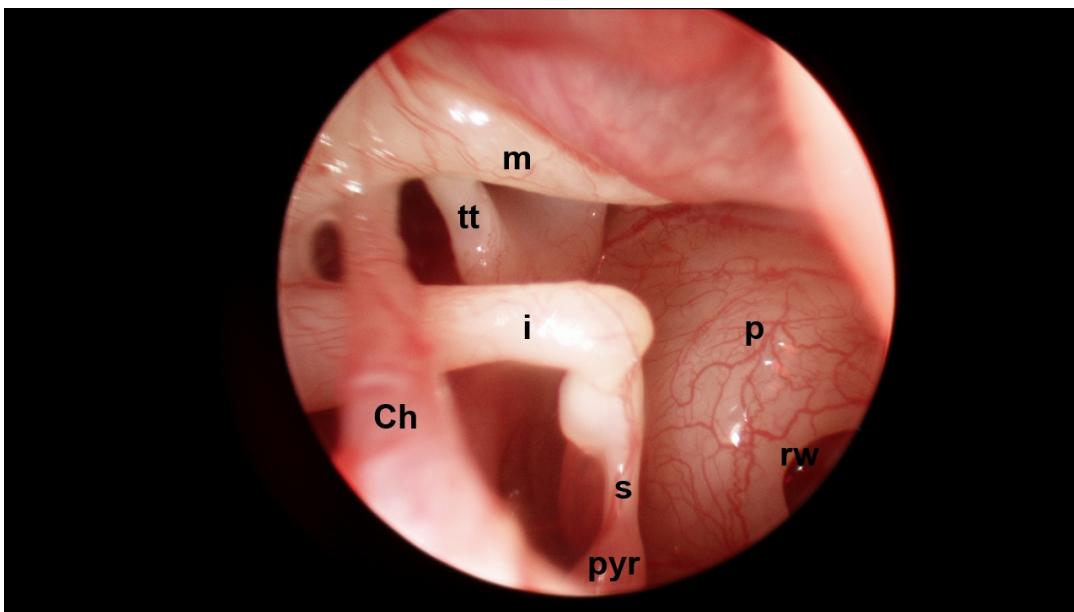


Fig. 1. Endoscopic view of the right ear posterior tympanic cavity using a 2.7 mm 30° rigid endoscope. The tympanomeatal flap is elevated anteriorly to the level of the malleus. Both the stapedius and tensor tympani tendons are easily seen. Ch chorda tympani; i incus; m malleus handle; p cochlear promontory; rw round window niche; s stapedius tendon originating from the pyramidal eminence (pyr); tt tensor tympani courses through a semicanal paralleling the Eustachian tube. It emerges from the cochleariform process and attaches to the underside of the malleus neck and manubrium

Under endoscopic visualization, the stapedius tendon is cut using a sharp straight instrument such as small Bellucci scissors. Tearing the stapedius tendon with a blunt instrument is not recommended as this can cause dislocation of the incudostapedial joint, stapes dislocation or oval window fistula with resultant hearing loss. Once cut, the stapedius tendon tends to have memory and snap back into place. Ideally a segment of the tendon should be removed to prevent the cut edges from healing together.

The tensor tympani tendon is visualized with a 30° endoscope and cut with a sharp angled instrument such as a joint knife commonly used in stapedectomy. Theoretically, an otologic laser could be used to cut both tendons and create a gap between the cut ends to prevent later regrowth. The surgeon then uses a straight or curved pick to check for completeness of tendon transection, while visually confirming it. Fig. 2 depicts both the stapedius and tensor tympani tendons have been cut.

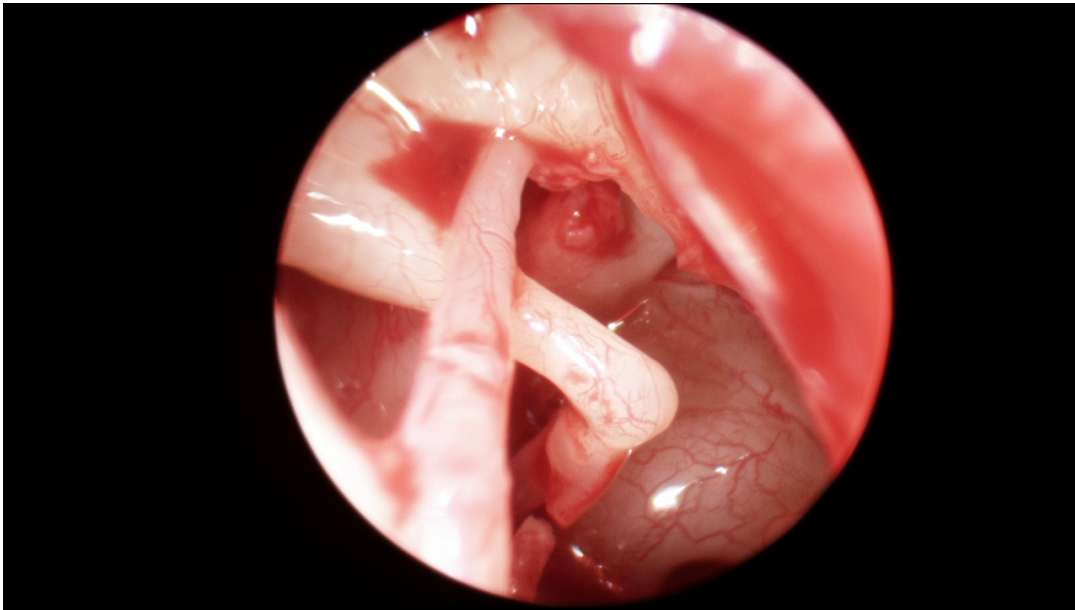


Fig. 2. Endoscopic view of the right ear tympanic cavity. The stapedius tendon is cut using a *straight sharp* instrument (eg. small Bellucci scissors) and the tensor tympani is cut using an *angled sharp* instrument (eg. joint knife). The wide-angle endoscopic view allows the surgeon to confirm complete transection of the target tendons

The tympanomeatal flap is then redraped to its normal anatomic position. The repair is stented in the usual fashion with pieces of absorbable gelatin sponge (eg. Gelfoam) and the ear canal can be optionally filled with bacitracin ointment. A cotton ball in the external auditory canal completes the dressing. The patient is awakened and extubated. Postoperatively, facial nerve function is checked in the recovery room and the patient is instructed to follow the usual tympanoplasty precautions such as limited nose blowing and water precautions.

The patient was seen in the office 1 week postoperatively and reported that the pulsatile tinnitus nearly-completely resolved. After 6 weeks, the operated ear healed completely, without any perforations, drum lateralization or ear canal scarring. Postoperative audiogram confirmed that hearing was preserved and drum mobility returned to normal. Preoperative pure tone average (PTA) was 35 dBHL and postoperative PTA was 37.5 dBHL. There was no postoperative dizziness or disturbance of taste. Pulsatile tinnitus had resolved.

3. DISCUSSION

The advent of endoscopic ear surgery techniques utilizing rigid endoscopes as the primary means of visualization since the 1990's has resulted in the development of multiple minimally-invasive surgical techniques that are gradually gaining acceptance and popularity in the community of otologic surgeons. While the microscope provides superb visualization and magnification, it is a line-of-sight instrument and many of the recesses of the tympanic cavity are not accessible to inspection. As a result, various techniques have been developed to aid in visualization of the middle ear recesses and epitympanum such as antrostomy and posterior tympanotomy (facial recess approach).

When performing surgery for middle ear myoclonus, the goal is to cut the stapedius and/or tensor tympani tendons. While the stapedius tendon is readily accessible, the tensor tympani is harder to visualize. As noted above, surgeons often have to blindly sweep and cut the tendon, elevate the drum off the malleus handle, or even raise an anterior tympanomeatal flap which is not recommended. The wide angle of view provided by the rigid Hopkins rod endoscopes allows the surgeon to readily visualize the tensor tympani, verify complete resection and avoid excessive tissue dissection or a postauricular approach.

In our patient, using the zero degree rigid endoscope, the stapedius tendon was visualized and sharply cut using Bellucci micro-scissors without the need for scutum curetting for exposure. With the use of a 30° rigid endoscope, the tensor tympani tendon was fully visualized between the cochleariform process and malleus neck, see Fig. 1. The tendon was cut under full visualization with a joint knife. Complete transection of the tendon was assured by inspection with the 30° scope and a Wullstein gently angled pick, see Fig. 2. With the use of endoscopes, there was no need to raise an extended tympanomeatal flap.

If the surgeon is inexperienced with endoscopic ear surgery, the technique can be combined with a classic microscopic approach. The canal injections and elevation of the tympanomeatal flap can be performed using the standard otologic microscope. The endoscope can then be used to identify the tendons and complete the procedure, making it effectively an endoscope-assisted procedure. The entire procedure can be done transcanal, without the need for a postauricular approach.

4. CONCLUSION

Endoscopic section of the tensor tympani and stapedius tendons is a new, minimally invasive treatment option for middle ear myoclonus that should be considered as a first line surgical treatment in patients who fail medical therapy. The endoscopic approach allows easier access and vastly superior visualization of the relevant anatomy. This in turn allows the surgeon to minimize dissection of normal tissue purely for exposure, in accordance with the principles of *functional endoscopic ear surgery* [16]. The entire operation, including raising the tympanomeatal flap and tendon section can be safely completed under visualization with a 2.7– 4.0 mm, zero or 30° angled rigid endoscope with good control of the pulsatile tinnitus.

CONSENT

All authors declare that written informed consent was obtained from the patient (or other approved parties) for publication of this case report and accompanying images.

ETHICAL APPROVAL

All authors hereby declare that this study has been examined and approved by the appropriate ethics committee and have therefore been performed in accordance with the ethical standards laid down in the 1964 Declaration of Helsinki.

COMPETING INTERESTS

Authors have declared that no competing interests exist.

REFERENCES

1. Badia L, Parikh A, Brooke GB. Management of middle ear myoclonus. *J Laryngol Otol.* 1994;108(5):380-382.
2. Ellenstein A, Yusuf N, Hallett M. Middle Ear Myoclonus: Two informative cases and a systematic discussion of myogenic tinnitus. *Tremor Other Hyperkinet Mov.* 2013;3:1-11.
3. Hidaka H, Honkura Y, Ota J, Gorai S, Kawase T, Kobayashi T. Middle ear myoclonus cured by selective tenotomy of the tensor tympani: Strategies for Targeted Intervention for Middle Ear Muscles. *Otol Neurotol.* 2013;34(9):1552-1558.
4. Bhimrao SK, Masterson L, Baguley D. Systematic review of management strategies for middle ear myoclonus. *Otolaryngol Head Neck Surg.* 2012;146(5):698-706.
5. Park SN, Bae SC, Lee GH, Song JN, Park KH, Jeon EJ, et al. Clinical characteristics and therapeutic response of objective tinnitus due to middle ear myoclonus: A Large Case Series. *Laryngoscope.* 2013;123(10):2516–2520.
6. East CA, Hazell JW. The suppression of palatal (or intra-tympanic) myoclonus by tinnitus masking devices: A preliminary report. *J Laryngol Otol.* 1987;101(12):1230-1234.
7. Bento RF, Sanchez TG, Miniti A, Tedesco-Marchesi AJ. Continuous, high frequency objective tinnitus caused by middle ear myoclonus. *Ear Nose Throat J.* 1998;77(10):814-818.
8. Oliveira CA, Negreiros Júnior J, Cavalcante IC, Bahmad F Jr, Venosa AR. Palatal and middle-ear myoclonus: A cause for objective tinnitus. *Int Tinnitus J.* 2003;9(1):37–41.
9. Howsam GD, Sharma A, Lambden SP, Fitzgerald J, Prinsley PR. Bilateral objective tinnitus secondary to congenital middle-ear myoclonus. *J Laryngol Otol.* 2005;119(6):489-491.
10. Liu HB, Fan JP, Lin SZ, Zhao SW, Lin Z. Botox transient treatment of tinnitus due to stapedius myoclonus: Case report. *Clin Neurol Neurosurg.* 2011;113(1):57-58.
11. Marchiando A, Per-Lee JH, Jackson RT. Tinnitus due to idiopathic stapedial muscle spasm. *Ear Nose Throat J.* 1983;62(1):8-13.
12. Klochoff I. The tensor tympani syndrome – A source of vertigo. Abstracts, Barany Society Ordinary Meeting in Uppsala, Sweden, June 1-3. 1978;31-32.
13. Grobman A, Grobman L, Balkany T. Adjunctive tenotomy during middle ear surgery. *Laryngoscope.* 2013;123(5):1272–1274.
14. Loader B, Beicht D, Hamzavi JS, Franz P. Tenotomy of the middle ear muscles causes a dramatic reduction in vertigo attacks and improves audiological function in definite Meniere's disease. *Acta Otolaryngol.* 2012;132(5):491–497.

15. Pollak N. Instrumentation and Operating Room Setup. In: Pollak N, editor. Endoscopic Ear Surgery. San Diego (CA): Plural Publishing. 2014;33-41. (In Press)
16. Pollak N. Principles of endoscopic ear surgery. In: Pollak N, editor. Endoscopic Ear Surgery. San Diego (CA): Plural Publishing. 2014;1-17. (In Press)

© 2014 Pollak et al.; This is an Open Access article distributed under the terms of the Creative Commons Attribution License (<http://creativecommons.org/licenses/by/3.0>), which permits unrestricted use, distribution, and reproduction in any medium, provided the original work is properly cited.

Peer-review history:

The peer review history for this paper can be accessed here:
<http://www.sciencedomain.org/review-history.php?iid=473&id=12&aid=4139>