

# Variations in the Branching Pattern of Coeliac Trunk: A Cadaveric Case Series

SANDHYA VIKAS YATAGIRI<sup>1</sup>, ASHWINI BALASAHEB NUCHHI<sup>2</sup>, VEENA SRINIVAS HARWALKAR<sup>3</sup>, RAVI SIDDANAGOUDA BULAGOUA<sup>4</sup>



## ABSTRACT

During routine cadaveric dissection for students, the authors found variations in three cadavers. A male cadaver of approximately 70 years of age showed a unique branch communicating the coeliac trunk with the Superior Mesenteric Artery (SMA). The right and left hepatic arteries gave smaller branches before entering into liver. In another male cadaver of approximately 60 years of age, the left hepatic artery was arising from the left gastric artery. The common hepatic artery gave rise to right gastric artery and gastroduodenal artery, after which it continued as right hepatic artery proper. This gave rise to cystic artery. The present series also observed quadrifurcation of coeliac trunk in a male cadaver of 70 years of age. It gave off four branches namely, splenic artery, left gastric artery, right hepatic artery and left hepatic artery. The gastroduodenal artery was arising from the left hepatic artery. The variations in the branching pattern of coeliac trunk is important for the surgeons during gastric surgeries, liver transplantation, pancreatic and gall bladder surgeries. Radiologists should be aware of such variations during reporting of Computed Tomography (CT) angiograms.

**Keywords:** Angiography, Communicating, Hepatic, Quadrifurcation, Segmental, Tripod

## INTRODUCTION

The coeliac trunk arises as one of the ventral branches of the abdominal aorta at the intervertebral disc level between the T12 and L1 vertebrae. The trunk usually divides into three branches, the common hepatic artery, the left gastric artery, the splenic artery. The coeliac trunk supplies the foregut [1]. The classical branching pattern of the coeliac trunk into the common hepatic artery, splenic artery and the left gastric artery, the Haller's tripod, was first described in 1756 by Haller [2]. Studies done on the variations in the coeliac trunk branching is commonly reported. Not all the cases are symptomatic. Cases of quadrifurcation [3,4] and pentafurcation [5] of the coeliac trunk are reported in which the surgeons need to be cautious during operations on the hepatic, gastric, pancreatic and surrounding regions. The pattern of variations observed in hepatic arteries, particularly the segmental hepatic arteries have to be mentioned specially in the coming era of segmental hepatic arterial chemoembolisation and radioembolisation. This information guided the authors to demonstrate the variations in the branches of coeliac trunk and its application in the human.

## CASE SERIES

During routine cadaveric dissection for students, the coeliac trunk shows variations in the branching pattern in three cadavers.

### Case 1

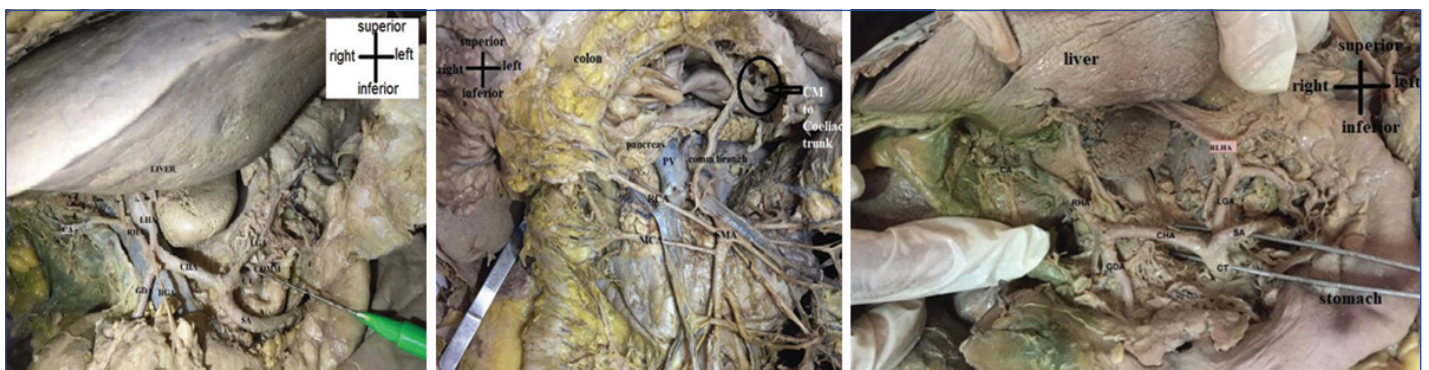A male cadaver of approximately 70 years of age, a unique branch communicating the coeliac trunk with the superior mesenteric artery was seen [Table/Fig-1,2]. The right and left hepatic arteries gave smaller branches before entering the liver. These are the segmental branches of the hepatic arteries before entering the liver.

### Case 2

A male cadaver of approximately 60 years of age showed that the left hepatic artery was arising from the left gastric artery [Table/Fig-3]. This is termed as replaced left hepatic artery. The common hepatic artery gave rise to the right gastric and gastroduodenal artery, then continued as the right hepatic artery. The right hepatic gave rise to the cystic artery.

### Case 3

As seen in [Table/Fig-4], there was quadrifurcation of the coeliac trunk in a male cadaver of 70 years of age. It gave off four branches:



**[Table/Fig-1]:** Dissected coeliac trunk and its branches which shows a unique communicating artery in a male cadaver.

CT: Coeliac trunk; SA: Splenic artery; CHA: Common hepatic artery; LGA: Left gastric artery; COMM: Unique communicating artery; LHA: Left hepatic artery; RHA: Right hepatic artery; CA: Cystic artery; GDA: Gastroduodenal artery; RGA: Right gastric artery; arrows indicate the segmental hepatic arteries

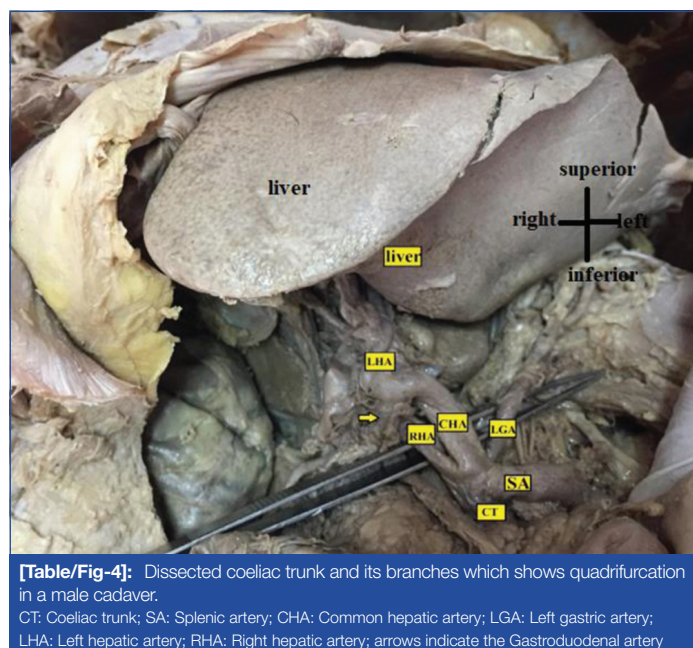
**[Table/Fig-2]:** Dissected superior mesenteric artery and its branches which shows a unique communicating branch communicating the superior mesenteric artery and the coeliac trunk.

PV: Portal vein; RCA: Right colic artery; MCA: Middle colic artery

**[Table/Fig-3]:** Dissected coeliac trunk and its branches which shows left hepatic artery (replaced left hepatic artery) arising from the left gastric artery. (Images from left to right)

CT: Coeliac trunk; SA: Splenic artery; CHA: Common hepatic artery; RHA: Right hepatic artery; LGA: Left gastric artery; RLHA: Replaced left hepatic artery; GDA: Gastroduodenal artery; LGA: Left gastric artery

splenic artery; left gastric artery; right hepatic artery; and left hepatic artery. The gastroduodenal artery was arising from the left hepatic artery.



**[Table/Fig-4]:** Dissected coeliac trunk and its branches which shows quadrifurcation in a male cadaver.

CT: Coeliac trunk; SA: Splenic artery; CHA: Common hepatic artery; LGA: Left gastric artery; LHA: Left hepatic artery; RHA: Right hepatic artery; arrows indicate the Gastroduodenal artery

The cause of death in one cadaver that is the case of quadrifurcation was complications due to carcinoma colon. In other two cases it was natural death.

## DISCUSSION

In the literature, a varying pattern of variations of the coeliac trunk have been described. The relevant ones are being discussed here. A unique communicating branch between the coeliac trunk and SMA is seen in the first case. This artery is similar to a branch documented by Fakoya AO et al., in 2019. The authors observed a fourth branch of the coeliac trunk (quadrifurcation) that communicated with the SMA at the point of origin of the inferior pancreaticoduodenal artery, which the author concludes to be the anterior inferior pancreaticoduodenal artery [3]. Hence, in the present case 1, the communicating artery can be concluded as the anterior inferior pancreaticoduodenal artery. The right and left hepatic arteries showed segmental branches outside the liver. Hemamalini H (2018) reported rare variations of coeliac trunk in 20 formalin-fixed abdomen specimens. Among them, the author observed the following variations, namely the absence of coeliac trunk with hepatomesenteric trunk, quadrifurcation with dorsal pancreatic artery arising from it, quadrifurcation with middle colic artery arising from it, left inferior phrenic artery arising from coeliac trunk, highly tortuous splenic artery supplying distal 1/3<sup>rd</sup> of the transverse colon and hepatosplenic trunk [4]. Unlike in the present study Quadrifurcation showed left hepatic, right hepatic, splenic and left gastric arteries. The left gastric artery, splenic artery, gastroduodenal artery, middle colic artery, and jejunoileal artery all came directly from the coeliac trunk in a case described by Lastoria DA et al., in 2022 [5]. Now the superior mesenteric artery gave rise to the proper hepatic artery. From the observations made, the present study shows one unique communicating branch between coeliac trunk and superior mesenteric artery, which is not a common finding in the literature. In a study by Panagouli E et al., in 2013, the coeliac trunk trifurcated into three primary branches in 89.42% of total. Bifurcation of the CT occurred in 7.40% of the pooled samples. Absence of the CT was the rarest variation, with a percentage of 0.38% hepatosplenomesenteric trunk was found in 49 out of the 12,196 cases (0.40%), and the coeliacomesenteric trunk presented an incidence of 0.76% (93/12,196). The authors detected other variations of the CT in 1.64% of the pooled cases

(199/12,196). A 14.9% of the cases (489/3278 samples) from the cadaveric series, 10.5% (675/6501 samples) from the imaging series, and 4.6% (104/2261) from the liver transplantation series showed variations [6].

Michels NA in 1955 described various patterns of hepatic arteries [7]. Here, the present case 2 belonged to type 2 Michels classification of hepatic arteries. That is the replaced left hepatic artery arising from the left gastric artery. A 10% of the individuals show this type of variation. Hiatts JR et al., also classified this as a type 2 variant which is seen in 9.7% of the individuals [8]. An angiographic study done by Favelier S et al., tries to understand the importance of these segmental hepatic arteries. Further the author explains the implications of such variations during radiological procedures [9]. Elsamaloty M et al., reported a replaced right hepatic artery arising directly from the coeliac trunk, a middle hepatic artery from the common hepatic artery and replaced left hepatic artery from the left gastric artery [10]. In the present case, the replaced left hepatic artery was arising from the left gastric artery. Noussios G et al., did a systematic review in 2017 where the study included 19000 patients. The author concludes that the hepatic artery shows asymptomatic variations in 20% of the population. The most common variation observed is the SMA giving off the replaced right hepatic artery [11]. Koshariya M et al., conducted a cadaveric study in 2021, out of 50 corpses, 76% of the cases showed the true Hallers tripod. In the remaining cases, the authors observed false Tripus Halleri. The author reports 6% hepatosplenic trunk with left gastric artery arising from the aorta, 2% hepatosplenic trunk with no normal left gastric artery, 2% hepatosplenic trunk with gastromesenteric trunk and 2% coeliacomesenteric trunk [12].

**Embryological basis:** There are four primitive splanchnic branches originating from the posterior aorta and anterior vertical anastomosis (Lang's anastomosis). The central two splanchnic branches usually disappear. The coeliac trunk is formed by the closure of the vertical anastomoses between last two roots. The left gastric artery is formed from the first root anterior segmental artery, the second becomes the splenic artery, the third becomes the common hepatic artery. The coeliacomesenteric trunk is formed by the persistence of the anterior vertical anastomosis and regression of the first or fourth root [13].

The normal anatomy of coeliac trunk and its varying branching pattern should be thoroughly studied before proceeding to surgical procedures on pancreas, duodenum, liver transplantation, infusion chemotherapy into hepatic arteries [4]. So one can go for the magnetic resonance imaging technique which helps the surgeon and the radiologist to find the variations in coeliac trunk and superior mesenteric arterial branches. There are various modes of detecting arterial variations even in the intrauterine life by ultrasonography [14]. By examining the foetal intestinal position one can predict the arterial variations. Sometimes the radiologist may detect variations in only 60-80% of the cases if preoperative imaging is done. This has got implications to prevent intraoperative and postoperative complications such as bleeding which might end up in ischaemia [14].

An anatomist may add to the existing knowledge of arterial variations by cadaveric studies which provide newer cases not known in the literature.

## CONCLUSION(S)

From the above observations, one can conclude that the surgeons and the radiologists must be aware of the variations in the branches of coeliac trunk. They have to be very accurate in interpretation of the images and also during procedures based on image guiding. It is also essential for the surgeons to be aware of these variations during oesophageal, gastroduodenal, hepatic, biliary, pancreatic, splenic and colonic surgical procedures. One should be cautious during the endovascular procedures on the liver such as radio or chemo embolisation procedures.

## REFERENCES

- [1] Standing S, Healy JC, Johnson D, Collins P, Borley NR, Crossman AR, et al. Posterior abdominal wall and retroperitoneum. *Gray's Anatomy*. 2016;41:1088.
- [2] Phillips B, Turco L, Reiter S, Murray EP, McDonald D, Cornell DL, Asensio JA, et al. Injuries to the celiac trunk: a systematic review of trauma to Haller's tripod. *International Journal of Medical Reviews*. 2016;3(4):5015-22.
- [3] Fakoya AO, Aguinaldo E, Velasco-Nieves NM, Barnes E, Vandevveer ZT, Morales-Marietti N, et al. A unique communicating arterial branch between the celiac trunk and the superior mesenteric artery: a case report. *Open Access Macedonian Journal of Medical Sciences*. 2019;7(13):2138.
- [4] Hemamalini H. Variations in the branching pattern of the celiac trunk and its clinical significance. *Anatomy and Cell Biology*. 2018;51(3):143-49.
- [5] Lastoria DA, Haiser A, Opoka V, Parry D. A new arterial variation involving a pentafurcated coeliac trunk. *Cureus*. 2022;14(7):e26508.
- [6] Panagoulis E, Venieratos D, Lolis E, Skandalakis P. Variations in the anatomy of the celiac trunk: a systematic review and clinical implications. *Annals of Anatomy-Anatomischer Anzeiger*. 2013;195(6):501-11.
- [7] Michels NA. Newer anatomy of the liver and its variant blood supply and collateral circulation. *Am J Surg*. 1951;112:503-24. Doi: 10.1016/0002-9610(66)90201-7.
- [8] Hiatt JR, Gabbay J, Busuttill RW. Surgical anatomy of the hepatic arteries in 1000 cases. *Annals of Surgery*. 1994;220(1):50.
- [9] Favelier S, Germain T, Genson PY, Cercueil JP, Denys A, Krausé D, Guiu B, et al. Anatomy of liver arteries for interventional radiology. *Diagnostic and Interventional Imaging*. 2015;96(6):537-46.
- [10] Elsameloty M, Schupp E, Ismail A, Borile C, Chun K, Sutton JM, et al. A rare anatomic variant of double replaced hepatic arteries: A case report and brief review of the anomalous hepatic vasculature literature. *The American Journal of Case Reports*. 2021;22:e930990-1.
- [11] Noussios G, Dimitriou I, Chatzis I, Katsourakis A. The main anatomic variations of the hepatic artery and their importance in surgical practice: review of the literature. *Journal of Clinical Medicine Research*. 2017;9(4):248.
- [12] Koshariya M, Khare V, Songra MC, Shukla S, Gupta A. Anomalous anatomical variations of coeliac trunk: a cadaveric study. *Cureus*. 2021;13(10):e19108.
- [13] Babu CR, Joshi S, Gupta KK, Gupta OP. Celiacomesenteric trunk and its variants a multidetector row computed tomographic study. *Journal of the Anatomical Society of India*. 2015;64(1):32-41.
- [14] Wozniak S, Florjanski J, Kordecki H, Podhorska-Okolow M, Domagala Z. Fetal sigmoid colon mesentery- In relevance in fetal ultrasound application. A pilot study. *Annals of Anatomy-Anatomischer Anzeiger*. 2018;216:152-58.

### PARTICULARS OF CONTRIBUTORS:

1. Associate Professor, Department of Anatomy, BLDEU's Shri BM Patil Medical College Hospital and Research Centre, Vijayapura, Karnataka, India.
2. Associate Professor, Department of Anatomy, BLDEU's Shri BM Patil Medical College Hospital and Research Centre, Vijayapura, Karnataka, India.
3. Assistant Professor, Department of Anatomy, BLDEU's Shri BM Patil Medical College Hospital and Research Centre, Vijayapura, Karnataka, India.
4. Professor and Head, Department of Anatomy, BLDEU's Shri BM Patil Medical College Hospital and Research Centre, Vijayapura, Karnataka, India.

### NAME, ADDRESS, E-MAIL ID OF THE CORRESPONDING AUTHOR:

Ashwini Balasaheb Nuchhi,  
Aashirwad Nilaya, Malaprabhanagar, Ashram Road Vijayapura-586103,  
Karnataka, India.  
E-mail: ashwini.nuchhi@bldedu.ac.in

### PLAGIARISM CHECKING METHODS: [Jain H et al.]

- Plagiarism X-checker: Mar 10, 2023
- Manual Googling: Apr 20, 2023
- iThenticate Software: Apr 25, 2023 (25%)

### ETYMOLOGY: Author Origin

### AUTHOR DECLARATION:

- Financial or Other Competing Interests: None
- Was informed consent obtained from the subjects involved in the study? No
- For any images presented appropriate consent has been obtained from the subjects. No

Date of Submission: **Mar 06, 2023**

Date of Peer Review: **Mar 30, 2023**

Date of Acceptance: **Apr 28, 2023**

Date of Publishing: **Jun 01, 2023**