

Ultrasound-Guided Greater Occipital Nerve Hydrodissection for Treatment of Cervicogenic Headache: A Case Report

Paul J. Ryan* , Dominic C. Harmon

Department of Anaesthesia and Pain Medicine, University Hospital Limerick, Dooradoyle, Limerick, Ireland
Email: *pauljeromeryano30@gmail.com, harmondominic@gmail.com

How to cite this paper: Ryan, P.J. and Harmon, D.C. (2023) Ultrasound-Guided Greater Occipital Nerve Hydrodissection for Treatment of Cervicogenic Headache: A Case Report. *Pain Studies and Treatment*, 11, 1-8.

<https://doi.org/10.4236/pst.2023.111001>

Received: January 6, 2023

Accepted: January 28, 2023

Published: January 31, 2023

Copyright © 2023 by author(s) and Scientific Research Publishing Inc.
This work is licensed under the Creative Commons Attribution International License (CC BY 4.0).

<http://creativecommons.org/licenses/by/4.0/>



Open Access

Abstract

We describe an innovative technique of ultrasound-guided greater occipital nerve (GON) hydrodissection for treatment of cervicogenic headache and occipital neuralgia. A 35-year-old female presented to the pain clinic with severe chronic cervicogenic headache impacting her sleep, work and activities of daily living. Conservative management had failed to adequately resolve her pain. Ultrasound-guided suboccipital hydrodissection of the greater occipital nerve was performed with the patient in the prone position. After skin sterilization, the linear ultrasound transducer was oriented in a transverse orientation at the level of the C2-C3 vertebrae. The needle was advanced from medial to lateral “in-plane” under direct ultrasound visualization, until the needle was positioned at the C2 lamina. After confirming the needle tip position, 10 ml of hydrodissection fluid was injected with good visualization of distribution of the solution. The patient described immediate and significant improvement in her symptoms. She reported a sustained decrease in pain scores when followed up in the pain clinic at six and twelve weeks respectively. To the best of our knowledge this is the first application of ultrasound-guided hydrodissection of the GON for cervicogenic headache. It offers a novel, safe and effective technique to aid in the diagnosis and treatment of a common pain condition.

Keywords

Cervicogenic Headache, Neck Pain, Occipital Nerve, Hydrodissection, Ultrasound

1. Introduction

Cervicogenic headache is head pain referred to the head from a source in the

cervical spine [1]. It describes a headache in which there is clear involvement of the neck and possibly a neck-related aetiopathogenesis. Occipital neuralgia is a common component of cervicogenic headaches. Typically patients describe pain that begins with a deep sensation of pressure in the suboccipital region which can extend to the occipital, parietal and fronto-orbital regions and down to the shoulders [2]. It is a common and debilitating pain condition. Injection of the greater occipital nerve (GON) with local anesthetic and corticosteroids has been widely used in clinical practice for many years for patients who have frequent attacks of pain and tenderness in the suboccipital region [3] [4]. To the best of our knowledge this is the first application of ultrasound-guided hydrodissection of the GON for cervicogenic headache.

The GON arises from the dorsal root ganglion of C2 and C3, between the atlas and the lamina of C2 (Figure 1) [5]. It runs deep to the inferior oblique capitus (IOC) muscle. Then, it travels upward over the IOC to pierce the semispinalis capitis (SSC) muscle and runs deep to the trapezius muscle onto the posterior skull. The nerve emerges onto the posterior scalp region by perforating the aponeurotic fibers of the trapezius and the sternocleidomastoid muscle near their occipital attachment to the skull [6]. At this point, it can be found lying in a palpable groove medial to the artery and lateral to the occipital prominence [6]. Greater Occipital Nerve entrapment can occur at several different levels: between the atlas and axis, between the IOC and SSC muscles, at the level of piercing the SSC muscle, or where the nerve exits from the trapezius muscle aponeurosis [7]. This can lead to a variety of clinical presentations including pain and paraesthesia of the posterior scalp, temporal region and external ear. Also, it may present as an occipital neuralgia or cervicogenic headache picture [5].

There are several options in current practice for the treatment of occipital neuralgia. These include occipital nerve block, the use of botulinum toxin to relieve muscular spasm, radiofrequency lesioning, cryoneuroablation, occipital nerve stimulation, and surgical decompression [8]. Suboccipital hydrodissection of the GON is a novel technique for the treatment of occipital neuralgia and cervicogenic headache. Dr. Gabor Racz developed a suboccipital approach to the suboccipital space using fluoroscopic guidance to facilitate nerve decompression [9] [10]. This technique has not yet been reported before using ultrasound guidance. In this case report, we illustrate a new technique for suboccipital ultrasound-guided GON hydrodissection as a treatment of occipital neuralgia and cervicogenic headache.

2. Case Report

A 35-year-old female patient presented to our pain clinic complaining of severe pain in her occipital region for more than 12 months. The pain was dull and aching in character. This was associated with moderate to severe tenderness over the occipital area and nuchal prominence. It was also accompanied by tingling, numbness and hyperalgesia over the area of pain. The pain was aggravated by

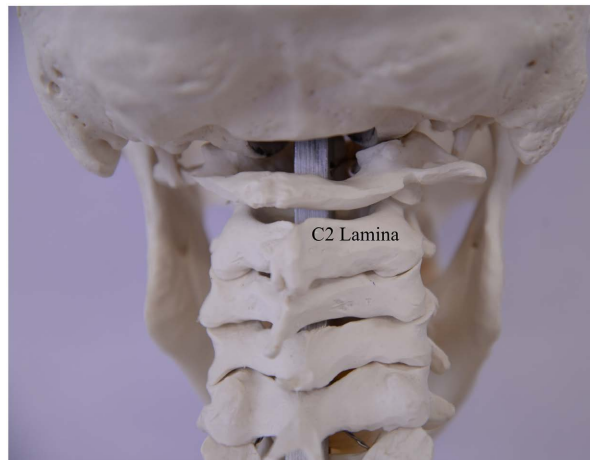

Figure 1. Posterior spinal anatomy.

lying down and by pressure on pillows to the back of her head. She reported partial and short-lived relief from simple oral analgesia including paracetamol and ibuprofen. There was no history of trauma to the head or upper cervical area.

She was also suffering from difficulty sleeping because of her headache and upper neck pain. This had a major impact on her daily activities and her work with the patient being unable to fulfill all of her work commitments. On examination, the pain was in the left upper cervical area and over the occipital area at the level of the nuchal ridge, with maximum tenderness to palpation over the GON. Her pain score was evaluated by the Numerical Analogue Scale [11] [12]. She reported her pain score as 8/10. The patient reported pain on active flexion and extension of the neck. However, there was no evidence of any limitation in her neck mobility with a normal range of motion and normal motor power.

Other causes were ruled out with history, examination and investigations. Routine bloods, x-ray and MRI imaging of the neck and head were undertaken with no obvious causative pathology identified. Conservative treatment with medications and physiotherapy had failed to adequately resolve the patient's pain. She continued to report a significant impairment to her quality of life so the decision was taken for interventional pain management. An appointment for GON steroid injection and suboccipital nerve hydrodissection was arranged. Before the procedure, a diagnostic GON injection was done under ultrasound guidance by injecting a small dose of local anaesthetic (3 ml lidocaine 2%). This confirmed GON entrapment as the source of the patient's symptoms.

A consultant anaesthetist and skilled assistant were present for the procedure. Written consent was obtained from the patient prior to the procedure for ultrasound-guided left GON hydrodissection. She was positioned in a prone position with neck in a flexed position and muscles relaxed. She was encouraged to breathe normally. The patient was attached to continuous oxygen saturation monitoring for the short duration of the procedure, with full resuscitation equipment available. An ultrasound machine (Sonosite[®] Micromaxx) with a high frequency (4 - 5 MHz) linear transducer was used to identify the relevant

anatomical structures. The procedure was performed under complete aseptic conditions with hands wash and sterile gloves applied. Skin sterilization was performed with 2% chlorhexidine and a sterile drape was applied to the area. The ultrasound transducer was inserted into a sterile sheath containing ultrasound gel. A thin layer of sterile gel was placed between the draped ultrasound transducer and the skin.

The ultrasound transducer was placed in the suboccipital area in transverse orientation at the level of C2-C3 vertebrae, where the GON originates and passes deep to the IOC muscle. The target point was the superior lamina of C2. The vertebral level was confirmed using the spinous processes, before the bifid transverse process of C2 was visualized as a hyperechoic line deep to the fascia (**Figure 2**). After determining the target point, 2 ml lidocaine 1% was infiltrated to form a superficial skin wheal at the medial edge of the transducer. A 22 Gauge cutting spinal needle was inserted “in-plane” beneath the transducer. The needle was advanced from a medial to lateral direction, under direct vision, until the needle was positioned at the trigger point of the C2 transverse process. Once the needle tip position was confirmed by ultrasound, a solution of 10 ml of hydrodissection fluid (9 ml normal saline and 1 ml 40 mg/mL triamcinolone) was injected slowly (**Figure 2**). The red arrow shows the needle path and the outlined red area displays the spread of hydrodissection fluid.

Pain score and Clinical examination was performed after 30 minutes and pain score recorded. At 30 minutes post procedure the patient described a pain score of 1/10. Of note, palpation over the occipital region as described above did not elicit pain. The patient was asked to repeat the previously painful motions, and she did not describe any worsening of her pain score of 1/10 during all ranges of motion. She reported a sustained reduction in pain scores when followed up in the pain clinic at 6 and 12 weeks respectively. She reported a pain score of 3/10 at 6 weeks and 4/10 at 12 weeks, without any use of oral analgesia. She reported improved sleep, improved mood and a greater quality of life having returned to performing her full working duties. Long-term follow-up of patient outcome will help to document duration of effect.

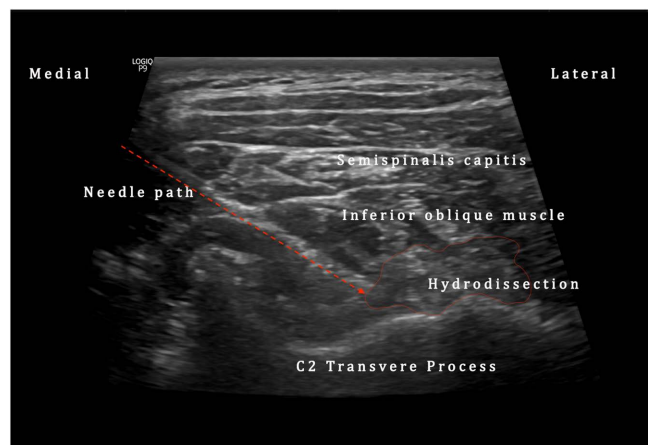


Figure 2. Labelled ultrasound image of occipital hydrodissection.

3. Discussion

This is a new technique of using real-time, high-resolution ultrasound to diagnose and treat GON entrapment, which is a common cause of occipital neuralgia and headache. Suboccipital GON hydrodissection for diagnosis and treatment of cervicogenic headache and occipital neuralgia has primarily been performed under fluoroscopic guidance up until this point, owing to its accuracy in identification of bony structures. However, the main limitations associated with this approach include exposure to ionizing radiation, the need for a contrast agent and cost issues. These limitations are particularly important in the field of pain medicine, as patients are likely to require repeated injections. For these reasons, the use of ultrasound-guided injections is an excellent and effective alternative that should be considered.

The benefits of this technique are significant. With appropriate training and experience in the use of ultrasound, it is more straightforward than the fluoroscopic guided GON hydrodissection and there is no risk of radiation and no need for radio-opaque dye as previously described by Dr. Gabor Racz [9]. Ultrasound guided block of the GON has shown a high success rate in the region of 90% [13] [14]. Moreover, evidence has shown that ultrasound techniques are easier to perform, require shorter time duration and are generally more acceptable for patients and physicians [14] [15]. Ultrasound has lower associated equipment costs and has the benefit of being easily adjustable to patient-specific requirements. If a patient is unable to lie in a prone position due to medical comorbidities, this procedure can be adapted to be performed in a sitting position using ultrasound guidance. The GON is well suited to access with ultrasound guidance due to its superficial nature and the excellent soft-tissue visualization achievable. Furthermore, visualization of the occipital artery may reduce the risk of intravascular injection compared to fluoroscopy. Doppler colour flow can be used to identify the pulsatile occipital artery, and can aid with identification of the GON, which is located medial to this artery. The subjective patient experience was good overall and the procedure was well tolerated.

Nerve hydrodissection is a novel technique that can be used in appropriate circumstances to release scar tissue or fascia from the entrapped nerves. Peripheral nerve entrapments are common but are an under recognized source of pain [16]. There is altered transmission because of mechanical irritation from impingement. Injections can aid in diagnoses, but they can also treat the underlying nerve entrapment by hydrodissection of the constricting tissues and the dilution and flushing out of inflammatory mediators, as well as the anti-inflammatory effect of injected corticosteroids. Injection of a volume of fluid into the deep fascial layers separates the entrapped nerve from surrounding bone or tendons [16]. Normally, the nerve moves smoothly, but entrapment causes a condition similar to adhesions with tethering of superficial and deep nerves. This leads to pain, nerve dysfunction and autonomic dysfunction. Nerve hydrodissection requires the skill of ultrasound identification of the nerves and careful

manipulation of the transducer and needle to inject the solution into the perineural area to release the affected nerve while avoiding intraneural injection. Precise and atraumatic injection techniques are essential to maximize the treatment value of any nerve injection for nerve entrapment [16]. We elected for hydrodissection with saline and corticosteroid solution, which has an excellent safety profile.

There are different locations where the GON can be injected under ultrasound-guidance: at the level of the occipital ridge (or the nuchal ridge), where the nerve is located medial to occipital artery and is easy to identify with Doppler guidance. Also, there is another site for nerve injection at the level of the bifid spinous process of C2 or suboccipital injection. Suboccipital GON hydrodissection can address the underlying lesion of occipital neuralgia and treat the exact site of GON entrapment at its origin.

This is a minimally invasive and safe intervention. It is easy to perform and is both cost and time efficient which are important considerations. It has a good safety profile with low risk of adverse effects. This report describes this novel technique demonstrating that GON hydrodissection performed in the prone position has potential a safe, feasible and effective option for the management of chronic cervicogenic headache and occipital neuralgia.

4. Conclusion

Ultrasound-guided GON hydrodissection technique offers a novel, safe and effective treatment method for the patient with medically refractory cervicogenic headache or occipital neuralgia.

Statements and Declarations

Availability of Data and Material/Data Transparency

This case report is an honest, accurate, and transparent account of the case being reported. No important aspects of the report have been omitted. Any queries should be directed via email to the corresponding author. Requests for reprints should also be addressed to the corresponding author.

Ethics Approval

This study is fully compliant with the ethical guidelines of the Research Ethics and Clinical Trials Committee of the University of Limerick Hospitals Group.

Consent to Participate

The patient described consented to participation and publication of the report as described.

Consent for Publication

The corresponding author has the right to grant on behalf of all authors and

does grant on behalf of all authors, an exclusive licence to PAIN Practice to permit this case report (if accepted) to be published in PAIN Practice editions.

Acknowledgements

We would like to extend our gratitude to the patient for her consent to publish this report.

Conflicts of Interest

The authors declare no conflicts of interest regarding the publication of this paper.

References

- [1] Bogduk, N. and Govind, J. (2009) Cervicogenic Headache: An Assessment of the Evidence on Clinical Diagnosis, Invasive Tests, and Treatment. *The Lancet Neurology*, **8**, 959-968. [https://doi.org/10.1016/S1474-4422\(09\)70209-1](https://doi.org/10.1016/S1474-4422(09)70209-1)
- [2] Antonaci, F., *et al.* (2005) Concepts Leading to the Definition of the Term Cervicogenic Headache: A Historical Overview. *The Journal of Headache and Pain*, **6**, 462-466. <https://doi.org/10.1007/s10194-005-0250-6>
- [3] Afridi, S., *et al.* (2006) Greater Occipital Nerve Injection in Primary Headache Syndromes-Prolonged Effects from a Single Injection. *Pain*, **122**, 126-129. <https://doi.org/10.1016/j.pain.2006.01.016>
- [4] Juškys, R. and Šustickas, G. (2018) Effectiveness of Treatment of Occipital Neuralgia Using the Nerve Block Technique: A Prospective Analysis of 44 Patients. *Acta Medica Lituanica*, **25**, 53. <https://doi.org/10.6001/actamedica.v25i2.3757>
- [5] Cesmebasi, A., *et al.* (2015) Occipital Neuralgia: Anatomic Considerations. *Clinical Anatomy*, **28**, 101-108. <https://doi.org/10.1002/ca.22468>
- [6] Moore, K.L. and Dalley, A.F. (2018) Clinically Oriented Anatomy. Wolters Kluwer India Pvt Ltd., Haryana.
- [7] Vital, J., *et al.* (1989) An Anatomic and Dynamic Study of the Greater Occipital Nerve (n. of Arnold). *Surgical and Radiologic Anatomy*, **11**, 205-210. <https://doi.org/10.1007/BF02337823>
- [8] Lauretti, G.R., Corrêa, S.W. and Mattos, A.L. (2015) Efficacy of the Greater Occipital Nerve Block for Cervicogenic Headache: Comparing Classical and Subcompartmental Techniques. *Pain Practice*, **15**, 654-661. <https://doi.org/10.1111/papr.12228>
- [9] Racz, G., Noe, C. and Justiz, R. (2009) A New Technique for Suboccipital Compartment Decompression. *Pain Practice*, **9**, 29.
- [10] Trescot, A.M., *et al.* (2016) Suboccipital Neuralgia and Decompression. In: Trescot, A.M., Ed., *Peripheral Nerve Entrapments: Clinical Diagnosis and Management*, Springer International Publishing, Cham, 171-181. https://doi.org/10.1007/978-3-319-27482-9_20
- [11] Hawker, G.A., *et al.* (2011) Measures of Adult Pain: Visual Analog Scale for Pain (VAS Pain), Numeric Rating Scale for Pain (NRS Pain), McGill Pain Questionnaire (MPQ), Short-Form McGill Pain Questionnaire (SF-MPQ), Chronic Pain Grade Scale (CPGS), Short Form-36 Bodily Pain Scale (SF-36 BPS), and Measure of Intermittent and Constant Osteoarthritis Pain (ICOAP). *Arthritis Care & Research*, **63**, S240-S252. <https://doi.org/10.1002/acr.20543>
- [12] Von Korff, M., Jensen, M.P. and Karoly, P. (2000) Assessing Global Pain Severity by

Self-Report in Clinical and Health Services Research. *Spine*, **25**, 3140-3151.

<https://doi.org/10.1097/00007632-200012150-00009>

- [13] Eichenberger, U., *et al.* (2006) Sonographic Visualization and Ultrasound-Guided Block of the Third Occipital Nerve: Prospective for a New Method to Diagnose C2-C3 Zygapophysial Joint Pain. *The Journal of the American Society of Anesthesiologists*, **104**, 303-308. <https://doi.org/10.1097/00000542-200602000-00016>
- [14] Finlayson, R.J., *et al.* (2013) A Randomized Comparison between Ultrasound- and Fluoroscopy-Guided Third Occipital Nerve Block. *Regional Anesthesia & Pain Medicine*, **38**, 212-217. <https://doi.org/10.1097/AAP.0b013e31828b25bc>
- [15] Narouze, S.N. and Provenzano, D.A. (2013) Sonographically Guided Cervical Facet Nerve and Joint Injections: Why Sonography? *Journal of Ultrasound in Medicine*, **32**, 1885-1896. <https://doi.org/10.7863/ultra.32.11.1885>
- [16] Trescot, A. and Brown, M. (2015) Peripheral Nerve Entrapment, Hydrodissection, and Neural Regenerative Strategies. *Techniques in Regional Anesthesia and Pain Management*, **19**, 85-93. <https://doi.org/10.1053/j.trap.2016.09.015>