

## Endoscopic Revision of Unsuccessful Dacryocystorhinostomy under Local Anesthesia

Ben Limbu<sup>1</sup>, Suresh BK. Rasaily<sup>2\*</sup> and Rohit Saiju<sup>1</sup>

<sup>1</sup>Department of Orbit, Plastic and Lacrimal Surgery, Tilganga Institute of Ophthalmology, Gaushala, Kathmandu, Nepal.

<sup>2</sup>Rapti Eye Hospital, Tulsipur -4, Dang Nepal.

### Authors' contributions

This work was carried out in collaboration among all authors. Author BL designed the study, analysed and wrote the protocol. Author SBKR analysed and search literatures and wrote the first draft of study. Author RS analysed and reviewed the manuscript. All authors read and approved for the final manuscript.

### Article Information

#### Editor(s):

(1) Dr. Panagiotis Tsikripis, University of Athens, Greece.

#### Reviewers:

(1) Leszek Sulkowski, regional Specialist Hospital, Poland.

(2) Harsh, Jaipur National University, India.

Complete Peer review History: <https://www.sdiarticle4.com/review-history/70937>

Original Research Article

Received 20 May 2021

Accepted 24 July 2021

Published 27 July 2021

### ABSTRACT

**Aims:** To evaluate etiological factors for unsuccessful Dacryocystorhinostomy (DCR) surgeries and surgical outcome after revisional endoscopic endonasal dacryocystorhinostomy (Re-EEDCR) surgery.

**Study Design:** Retrospective study.

**Place and Duration of Study:** Department of Oculoplastic surgery, Tilganga Institute of Ophthalmology, between December 2017 to November 2019.

**Methods:** All the consecutive cases of previously failed DCRs who underwent revisional endoscopic endonasal DCR under local anesthesia were included. Patients' medical records were reviewed for demographic profile, pre and intra-operative endoscopic findings during revisional surgery, post, the outcome of surgery. The potential causative factors for unsuccessful DCR were assessed and the surgical outcome of Re-EEDCR was evaluated.

**Results:** A total of 15 patients, 13 (86.7%) female and 2 (13.3%) male with failed DCR, who had undergone revisional En-DCR were evaluated. The mean age at revisional surgery was 40.53

\*Corresponding author: E-mail: [srasaly@gmail.com](mailto:srasaly@gmail.com);

±15.88 (range, 18-74 years). The mean duration from primary to Re-EEDCR was 19.93±31.73 months (range, 1-120). The most common causes attributed to a failure of unsuccessful DCR was intranasal adhesion 9(60%) followed by the inappropriate site of ostium 8(53.3%), inadequate marsupialization of sac 6(40%), granuloma formation 2(13.3%), and inadequate ostium site (6.6%). The overall success rate was 93.3% (14/15) without any important intra or postoperative complications.

**Conclusion:** The most common cause for failed DCR was intranasal adhesions. A revision surgery with endoscopic endonasal approach under local anesthesia can significantly reduce overall surgery time and avoids the risk of further skin scarring. It is a safe and an effective option in the management of unsuccessful DCR surgery.

*Keywords: Endonasal Endoscopic DCR; Unsuccessful DCR; Failed DCR; Revision DCR; Local anesthesia.*

## 1. INTRODUCTION

External Dacryocystorhinostomy (Ex-DCR) is a gold standard surgical procedure in the management of nasolacrimal duct obstruction. The Ex-DCR procedure involves removal of nasal bone overlying the lacrimal sac and creating an anastomosis between lacrimal and nasal mucosa leading to free flow of tear from common canaliculi to the nasal cavity. Despite the high reported success rate among Ex-DCR which ranges between 63% to 97% [1-3], epiphora recurs among unsuccessful Ex DCR surgery patients. When Ex-DCR surgery proves to be unsuccessful, it can lead to significant dissatisfaction among patients. Different available practices for revision of unsuccessful Ex-DCR are revision with Ex-DCR, endoscopic endonasal DCR(EEDCR), and trans canalicular diode laser-assisted revision. Revision with Ex-DCR can be challenging access to anastomosis site due to preexisting scarring, additional skin scar, and prolonged duration of surgery. Similarly, trans canalicular diode laser-assisted revision may not be accessible or cost-effective for developing countries. Since bone osteotomy is usually performed in a reasonable amount in Ex-DCR and to avoid scar tissue to access the anastomosis site, endo-nasal endoscopic guided DCR revision with local anesthesia can be a good alternative surgery in addressing both bony ostium, lacrimal sac, and adhesions from the nasal side [1,4-10].

Many factors may be responsible for the failure of Ex DCR surgery, leading to the inadequate opening of the bony ostium, inappropriate site of the ostium, inappropriate marsupialization of lacrimal sac, development of intranasal adhesion over surgical site obstructing tear flow and nasal mucosal granulations [3-9].

To our knowledge, there is no literature providing information on this novel approach in the revision of unsuccessful Ex-DCR using endoscopic guided DCR surgery under local anesthesia, though the same procedure under general anesthesia has been explained previously. The purpose of this study is to evaluate the anatomical and physiological success rate of endoscopic DCR revision in unsuccessful Ex-DCR.

## 2. METHODOLOGY

This is a hospital-based, consecutive, retrospective study among patients who underwent revision DCR surgery via endoscopic endonasal approach under local anesthesia for anatomical unsuccessful external DCR surgeries from Dec 2017 to Nov 2019. Patients who failed to complete 6 months' follow-up, incomplete records, and revision of unsuccessful DCR through external DCR approach were excluded from the study. Among the total 15 eligible study patients during the study period, 11 patients' previous surgery was performed at our hospital, and 4 patients had surgery outside our hospital as per our electronic medical records. Patient records were reviewed for demographic profile, finding of endoscopic nasal examination before surgery, intraoperative notes during revision, post-operative events, the outcome of surgery. The potential cause for failure of previous DCRs was assessed based on pre-operative endoscopic evaluation and intraoperative notes during revision surgery.

The success of the surgery was defined as the subjective complaint of complete resolution of epiphora and patent lacrimal passage on the syringing test. Inadequate osteotomy was defined as bone removal within which the tear

sac including its fundus is incompletely exposed. Inappropriate ostium location or ostium malposition was defined as limited osteotomy, which is localized inferiorly, anteriorly, or posteriorly about the interior common opening. Inappropriate sac marsupialization was defined as failure to attain full-thickness sac wall cut along its entire length and failure to reflect the lacrimal sac flaps noted intraoperatively.

All the revision surgeries were done by a single senior oculoplastic surgeon under local anesthesia. Patients were subjected to a nasal spray of 10% Adrenaline solution on the operating nostril and nasal packing with ribbon gauze containing Oxymetazoline 0.05% plus Adrenaline 1:1000 thirty minutes before surgery. After a standard method of cleaning and draping the surgical area, endoscopic nasal evaluation was performed using a 4mm, 0-degree telescope. Additional local anesthesia (2% Lidocaine with Adrenaline 1:10,000 plus 0.5% Bupivacaine) was infiltrated into the lateral wall of the nose, middle turbinate, nasal septum, and externally over anterior ethmoidal nerve through transcaruncular route and infraorbital nerve block. After meticulous evaluation of the nasal cavity, all appropriate surgical steps were adopted as per the need of the existing condition.

A power drill was attempted and used whenever needed and possible. After excising the scar tissue obstructing the tear drainage area and removal of remnant nasal or lacrimal flaps, a silicone tube was placed and secured with Watzke sleeve borrowed from Vitreo-retina unit into the lacrimal drainage system. Finally, before the nasal pack is applied, injection triamcinolone 0.2 -0.4ml is injected around the nasal mucosa around the bony ostium and the nasal pack was removed after 24 hours. The patient was discharged the same day of surgery with post-

operative oral antibiotics and topical antibiotic - steroid eye drop four times a day for 1 week. The patient was advised to follow up visit after 1 week, 1 month, 3 months, and 6 months of surgery. After a week, each patient was evaluated for subjective symptoms of epiphora and prescribed with only topical antibiotics eye drop four times a day till the silicone tube was removed. Each patient was evaluated for the anatomical success of surgery at 3 months after silicone tube removal and 6 months of surgery by irrigating the lacrimal drainage system using saline in a 20 G cannula.

Data were entered into a customized datasheet in Microsoft Excel and analyzed using Statistical Package for Social Sciences version 20 (SPSS, Inc. Chicago, IL, USA).

### 3. RESULT

A total of 15 revisions of endo-nasal endoscopic DCRs were performed over the study period. The mean age of surgery was 40.53 ±15.88 (range, 18-74 years). Of the 15 patients, 13 (86.7%) were female and 2 (13.3%) male with a male: female ratio of 1: 6.5. Out of the total, 9 (60%) revision DCR was performed on the left side and 6 (40%) right side. The majority of cases 11(77.3%) had previously undergone Ex DCR in our institute whereas 4(26.7%) cases were referred from elsewhere for revision surgery. Among 2 cases who underwent multiple attempts of external DCR, 1(6.6%) had undergone Ex-DCR twice elsewhere before referral and, the other case 1 (6.6%) had undergone revision Ex-DCR at our institute. The mean duration from first DCR surgery to revision endoscopic DCR was 19.93±31.73(range, 1-120 months). The baseline characteristics of previously failed DCRs are as shown in Table.1.

**Table 1. Baseline characteristics of failed DCRs**

<b>Characters</b>	
<b>Mean age Years ± SD (Range)</b>	40.53 ±15.88 (18-74 years).
<b>Gender</b>	Male 2/15(13.3%) Female 13/15(86.7%)
<b>Laterality</b>	Right 6/15(40%) Left 9/15(60%)
<b>Previous DCR Surge</b>	Study Center 11(77.3) Elsewhere 4(26.7%)
<b>Mean duration of unsuccessful DCR to revision En-DCR</b>	<b>Months ± SD (Range)</b> 19.93±31.73(1-120 months)

Intraoperative endoscopic evaluation among unsuccessful DCR surgeries in our study revealed most frequent etiological factors responsible for unsuccessful DCR surgeries as intranasal adhesion in 9(60%) cases followed by the inappropriate site of ostium 8(53.3%) and inadequate marsupialization of sac 6(40%). The Fig. 1. Illustrates the various etiological factors for failed DCR. Of the 11 (73.3%) patients with more than one cause, 9 (60%) had 2, and 2 (13.3%) had 3 causes whereas 4(26.7%) had a single cause.

There were no important intra or postoperative complications except mild epistaxis on day 1 of surgery. Some of the patients in our study had complained of watering during 1st week of surgery which gradually stopped within one month of follow-up. The functional and anatomical success rate was found to be 93.3%(14/15). Only, 1 patient out of 15 patients (6.7%) had complaint of post-operative watering since day 1 that persisted even at 6-months and regurgitation of clear fluid from opposite punctum noticed on syringing test at 6 months. The reason for unsuccessful in revisional En-DCR was found to be re-adhesion of intranasal tissue at common. The anatomical success and failure rates are as shown in Table 2.

#### 4. DISCUSSION

Dacryocystorhinostomy is the most effective surgery for creating an anastomosis between the lacrimal sac and nasal cavity bypassing the nasolacrimal duct. The failure rate of Ex-DCR is reported very low in our previous study [11]. However, it's very useful to identify the causative factors for the failure of DCR for planning re-operation or further management. We reviewed 15 previously failed Ex-DCR patients comprising 13(86.7%) female and 2(13.3%) male with a male: female ratio of 1:6.5 in which 9 (60%) were left-sided DCR. The majority of patients in our study were female like other studies 83.3% female [12], 92.15% [9], 77.5% [13], 62% [5], 66.7% [14]. The female preponderance in our study is due to a higher incidence of nasolacrimal duct obstruction in females owing to narrower nasolacrimal canal diameter.

The present study reported the mean age at the time of revisional surgery  $40.53 \pm 15.88$  years (range of 18-74) which is similar to  $37.19 \pm 13.62$  years in a study [8]. However, the higher mean age of presentation was reported as  $59.0 \pm 15.6$  years [5], 61 years [12], 64 years [7], and  $48.95 \pm 12.59$  years (range, 19–69) years [13] and 46.9

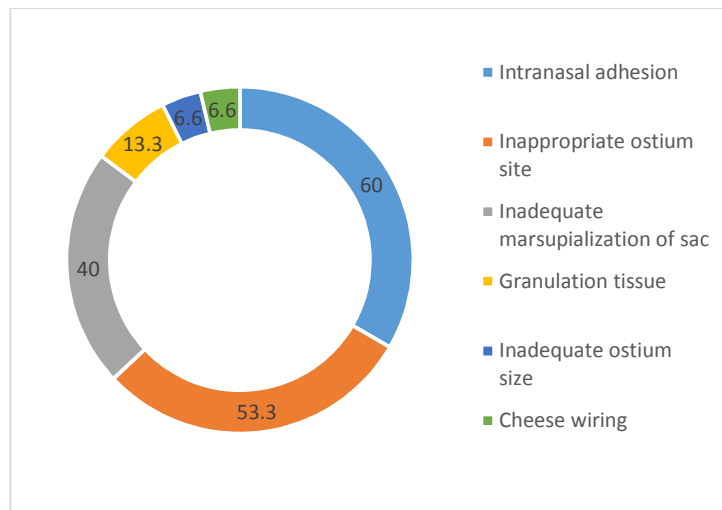


Fig. 1. Etiology of unsuccessful DCR surgeries

Table 2. Surgical outcome of revisional endoscopic endonasal DCR surgeries

Characters	Number	Percentage (%)
Success	14	93.3
Failure	1	6.7

14.1 years [15]. Similarly, the mean duration from primary Ex-DCR to revisional endoscopic DCR was  $19.93 \pm 31.73$  months (range, 1-120 months) which is similar to 21.2 months (range, 5–48 months) in the previous study [12] and inconsistent with findings 3 years [5] and  $6.5 \pm 5.7$  years [15].

There are several anatomical and functional factors responsible for the failure of external DCR. In our study, intranasal adhesion (60%) was most common followed by the inappropriate site of ostium (53.3%), inadequate marsupialization of sac (40%), granuloma formation at common canaliculi opening (13.3%), inadequate size of ostium (6.6%) and cheese wiring (6.6%). The intranasal adhesion (30%), inadequate size of ostium (12.3%), septal deviation (12.3%), and granuloma (9.2%) are also reported as common causes of failure in the study [16] analyzing of 65 failed DCRs which are consistent with our findings. The higher frequency of intranasal adhesion, inappropriate site, and size of ostium in our study is due to inadequate visualization of the nasal cavity and the learning curve of an inexperienced surgeon. However, inappropriate ostium site was reported as the most common causes for failure in 81.5% of cases [9], 83% [17], and 53.7% [18] followed by inappropriate marsupialization of lacrimal sac 60.2% [8]. The results of our study with regard to granuloma formation at the ostium site (13.3%) are consistent with the previous studies [19-21]. Of the 11(73.3%) patients with multifactorial cause, 9 (60%) had 2 and 2 (13.3) had 3 causes whereas 4(26.7%) had single causes for failed DCR which is inconsistent with 52.2% of patients with more than one cause, 36.5% had 2, and 15.7% had 3 pathologies reported in the literature [15].

In order to achieve a higher success rate of revisional endoscopic DCRs, we performed some adjunctive procedures intraoperatively with a magnified endoscopic view. Excess mucosa and scar tissue were carefully resected with a special punch to prevent fibrosis of the ostium in the future. An additional procedure like partial middle turbinectomy was performed in 1 case and the ostium was optimized in location and size with removing the obstructing bone in most cases. Granuloma tissue encountered intraoperatively in 2 cases was excised and hemostasis was maintained with electrocautery. We routinely used silicon tubes in all of our cases as they were previously failed DCR and on top with belief that silicon stent is required in a

technique where adjacent flaps of the lacrimal sac and nasal mucosa are not sutured. However, the use of DCR tube is considerable controversy in accordance with relevant literature in which some authors claim best results with the use of a tube [22,23] whereas others believe in the formation of granuloma tissue, discomfort, and extra cost with DCR tube [24,25]. The duration of DCR tubing is another controversy, however, we kept the tube for 3 months to ensure the permeability of the new draining pathway during the postoperative healing period [21].

Some of the patients in our cases had complained of watering till 1 month of surgery which gradually resolved till 3 months of follow-up. One patient had epistaxis on POD 1 which was resolved with nose packing with ribbon gauze soaked with Adrenaline 1:1000 and Oxymetazoline 0.05%. However, 1 patient had persistent watering till the end of 6 months of revisional surgery. We observed regurgitation of clear fluid from opposite punctum on syringing performed at 3 and 6 months of follow-up. We observed the presence of intranasal adhesion and considered a failed revision endoscopic DCR. He was then advised for revision En-DCR but Covid pandemic started and he lost to follow-up thereafter. The rest of the patients were free of symptoms and patent on syringing at 3- and 6-months follow-up visits. Based on the clinical features, symptoms free, and a patent on syringing at 6 months after surgery, the anatomical as well as the functional success rate in the current study was estimated to be 93.3%(14/15). However, the reported success rate of revisional endoscopic DCR is between 75% to 85% in the literature. [13,26]

The higher success rate in our study is similar to that reported in various studies 90% [21], 91.3% [12], 98.8% [27], and 89% [28]. Despite the use of only local anesthesia among revision of unsuccessful DCR by endonasal endoscopic DCR, we observed a higher success rate among our study patients which might be due to meticulous pre-operative endoscopic evaluation of the previously operated site and entire nasal cavity, careful handling of the mucosal lining of the nasal cavity, and creating appropriate site and size of ostium among our study population. The use of local anesthesia in our study avoided the long surgery schedule queue for patients, need for general anesthesia, cost, and morbidity associated with general anesthesia. And at the same time, the endonasal endoscopic approach lets us quicker access to the appropriate surgical

site thereby significantly reducing overall surgery time and avoiding further skin scars.

## 6. CONCLUSION

The most common cause for unsuccessful DCR surgery was found to be intranasal adhesions in our study. Based on this fact, External Dacryocystorhinostomy is merely a time-consuming and more invasive procedure than approaching the problem from the nasal side. A revisional endoscopic endonasal DCR under local anesthesia can significantly reduce overall surgery time and avoids the risk of further skin scarring in addressing unsuccessful DCR Surgery. Our study results demonstrated that the endoscopic endonasal DCR under local anesthesia is a safe and an effective option in the management of unsuccessful DCR surgery.

## ETHICAL APPROVAL

Ethical approval was obtained from the Institutional Review Committee of Tilganga Institute of Ophthalmology.

## CONSENT

Patient consent was deemed not required since this study was retrospective.

## LIMITATION OF STUDY

This is a retrospective study with relatively small sample size. Therefore, well designed prospective study with larger sample size is recommended to assess the outcome of the role of En-DCR for revision of unsuccessful DCR Surgery.

## DISCLAIMER

The products used for this research are commonly and predominantly use products in our area of research and country. There is absolutely no conflict of interest between the authors and producers of the products because we do not intend to use these products as an avenue for any litigation but for the advancement of knowledge. Also, the research was not funded by the producing company rather it was funded by personal efforts of the authors.

## ACKNOWLEDGEMENT

We would like to express our sincere thanks to Mr. Sudhatma Karki and Department of

Information and Technology for providing electronic medical records.

## COMPETING INTERESTS

Authors have declared that no competing interests exist.

## REFERENCES

1. Kumar CA, Kulkarni N, Lathi A, Gupta A, Rashinkar S, Roy A, Maloo F. Study of causes of failure in external DCR and endonasal DCR. Indian Journal of Basic and Applied Medical Research – Otorhinolaryngology special issue. 2017;6(2):26-30.
2. Katuwal S, Aujla JS, Limbu B, Saiju R, Ruit S. External dacryocystorhinostomy: do we really need to repair the posterior flap? Orbit. 2013;32(2):102-6. DOI:10.3109/01676830.2013.764451, PMID 23514023.
3. El-Guindy A, Dorgham A, Ghoraba M. Endoscopic revision surgery for recurrent epiphora occurring after external dacryocystorhinostomy. Ann Otol Rhinol Laryngol. 2000;109(4):425-30. DOI:10.1177/000348940010900414, PMID 10778899.
4. Liang J, Hur K, Merbs SL, Lane AP. Surgical and anatomic considerations in endoscopic revision of failed external dacryocystorhinostomy. Otolaryngol Head Neck Surg. 2014;150(5):901-5. DOI: 10.1177/0194599814524700, PMID 24596236
5. Yarmohammadi ME, Ghasemi H, Jafari F, Izadi P, Nadoushan MJ, Chin NS. Teamwork endoscopic endonasal surgery in failed external dacryocystorhinostomy. J Ophthalmic Vis Res. 2016;11(3):282-6. DOI: 10.4103/2008-322X.188396, PMID 27621786.
6. Ghasemi H, Asghari Asl SA, Yarmohammadi ME, Jafari F, Izadi P. External dacryocystorhinostomy; success rate and causes of failure in endoscopic and pathologic evaluations. Iran J Pathol. 2017;12(3):189-94. DOI:10.30699/ijp.2017.24234, PMID29531542.
7. Hull S, Lalchan SA, Olver JM. Success rates in powered endonasal revision surgery for failed dacryocystorhinostomy in a tertiary referral center.

- Ophthal Plast Reconstr Surg. 2013;29(4):2 67-71.  
DOI:10.1097/IOP.0b013e3182916556, PMID 23719197.
8. Dave TV, Mohammed FA, Ali MJ, Naik MN. Etiologic analysis of 100 anatomically failed dacryocystorhinostomies. Clin Ophthalmol. 2016;10(1419):1419-22. DOI:10.2147/OPHTH.S113733, PMID27555 748.
  9. Jan SAS, Wani J, Riaz R, Nazir O. Evaluation of dacryocystorhinostomy failure with computed tomographic dacryocystography. Int J Res Med Sci.2017;5(12):5197-202. DOI: 10.18203/2320-6012.ijrms20175130.
  10. Yoon JM, Nam SW, Woo KI, Kim YD. Transcanalicular diode laser-assisted revision surgery for failed dacryocystorhinostomy with or without distal or common canalicular obstruction. Ophthal Plast Reconstr Surg. 2018;34 (3):291-5. DOI:10.1097/IOP.0000000000000961, PMID 28723734.
  11. Rasaily S, Limbu B, Saiju R. External vs. endonasal Endoscopic dacryocystorhinostomy: surgical Success and Patient Satisfaction. Int J Ophthal Pathol. 2018;1-5.
  12. Ali MJ, Psaltis AJ, Wormald PJ. Long-term outcomes in revision powered endoscopic dacryocystorhinostomy. Int Forum Allergy Rhinol. 2014;4(12):1016-9. DOI: 10.1002/alr.21398, PMID 25175719.
  13. Akcay E, Yuksel N, Ozen U. Revision external dacryocystorhinostomy results after a failed dacryocystorhinostomy surgery. Ophthalmol Ther. 2016;5(1):75-80. DOI: 10.1007/s40123-016-0048-4, PMID 27074846.
  14. Kashkouli MB, Parvaresh MM, Modarreszadeh M, Hashemi M, Beigi B. Factors affecting the success of external dacryocystorhinostomy. Orbit. 2003;22(4): 247-55. DOI: 10.1076/orbi.22.4.247.17255, PMID 14685898.
  15. Altin Ekin M, Karadeniz Ugurlu S, Aytogan H, Sahin Atik S. Failure in Revision Dacryocystorhinostomy: A Study of Surgical Technique and Etiology. J Craniofac Surg. 2020;31(1):193-6. DOI:10.1097/SCS.00000000000005829, PMID 31369514.
  16. Elmorsy SM, Fayk HM. Nasal endoscopic assessment of failure after external dacryocystorhinostomy. Orbit. 2010;29(4): 197-201. DOI: 10.3109/01676831003669961, PMID 20812836.
  17. Gökçek A, Argin MA, Altintas AK. Comparison of failed and successful dacryocystorhinostomy by using computed tomographic dacryocystography findings. Eur J Ophthalmol. 2005;15(5):523-9. DOI: 10.1177/112067210501500501.
  18. Welham RA, Wulc AE. Management of unsuccessful lacrimal surgery. Br J Ophthalmol. 1987;71(2):152-7. DOI:10.1136/bjo.71.2.152, PMID 3828266.
  19. Önerci M, Orhan M, Öğretmenoğlu O, Irkeç M. Long-term results and reasons for failure of intranasal endoscopic dacryocystorhinostomy. Acta oto-laryngol. 2000;120(2):319-22. DOI:10.1080/000164800750001170, PMID 11603798.
  20. Narioka J, Ohashi Y. Transcanalicular-endonasal semiconductor diode laser-assisted revision surgery for failed external dacryocystorhinostomy. Am J Ophthalmol. 2008;146(1):60-8. DOI:10.1016/j.ajo.2008.02.028, PMID1843 9559.
  21. Demarco R, Strose A, Araújo M, Valera FCP, Moribe I, Anselmo-Lima WT. Endoscopic revision of external dacryocystorhinostomy. Otolaryngol Head Neck Surg. 2007;137(3):497-9. DOI: 10.1016/j.otohns.2007.03.023, PMID 17765783.
  22. De Souza C, Nissar J. Experience with endoscopic dacryocystorhinostomy using four methods. Otolaryngol Head Neck Surg. 2010;142(3):389-93. DOI: 10.1016/j.otohns.2009.12.031, PMID 20172386.
  23. Hartikainen J, Antila J, Varpula M, Puukka P, Seppä H, Grénman R. Prospective randomized comparison of endonasal endoscopic dacryocystorhinostomy and external dacryocystorhinostomy. Laryngoscope. 1998;108(12):1861-6. DOI:10.1097/00005537-199812000-00018, PMID 9851505.
  24. Shah Z, Hussain I, Khattak N, Iqbal M. A review of 144 cases of dacryocystorhinostomy. Pak. J Ophthalmol. 2009;30; 25(2).

25. Unlu HH, Gunhan K, Baser EF, Songu M. Long-term results in endoscopic dacryocystorhinostomy: is intubation really required? Otolaryngol Head Neck Surg. 2009;140(4):589-95.  
DOI: 10.1016/j.otohns.2008.12.056, PMID 19328352.
26. Korkut AY, Teker AM, Yazici MZ, Kahya V, Gedikli O, Kayhan FT. Surgical outcomes of primary and revision endoscopic dacryocystorhinostomy. J Craniofac Surg. 2010;21(6):1706-8.  
DOI:10.1097/SCS.0b013e3181f3c6c1, PMID 21119404.
27. Al Huthail RR, Al-Faky YH. Late endoscopic evaluation of the ostium size after external dacryocystorhinostomy. Eur J Ophthalmol. 2020;24:1120672120976044.  
Doi:10.1177/1120672120976044, PMID 33233950.
28. Zeldovich A, Ghabrial R. Revision endoscopic dacryocystorhinostomy with betamethasone injection under assisted local anaesthetic. Orbit. 2009;28(6):328-31.  
DOI: 10.3109/01676830903104686, PMID 19929653.

© 2021 Limbu et al.; This is an Open Access article distributed under the terms of the Creative Commons Attribution License (<http://creativecommons.org/licenses/by/4.0>), which permits unrestricted use, distribution, and reproduction in any medium, provided the original work is properly cited.

*Peer-review history:*

*The peer review history for this paper can be accessed here:  
<https://www.sdiarticle4.com/review-history/70937>*