



McIndoe Operation without Skin Graft: A New Neovaginal Prosthesis of Polylactic Acid (PLA)

**Pedro Acién^{1,2*}, Maribel Acién^{1,2,3}, Miguel-Angel Oliva-Meyer⁴,
Miguel Sánchez-Lozano⁴ and Javier Martínez-García⁴**

¹Department of Public Health, Sc.H. and Gynecology, School of Medicine, Miguel Hernandez University, Campus of San Juan, 03550 Alicante, Spain.

²Instituto de Ginecología P.A.A. 03002 Alicante, Spain.

³Service of Obstetrics and Gynecology, San Juan University Hospital, Campus of San Juan, 03550 Alicante, Spain.

⁴Department of Mechanical Engineering and Energy, Miguel Hernandez University, Campus of Elche, 03202 Alicante, Spain.

Authors' contributions

This work was carried out in collaboration between all authors. Author PA designed the study, wrote the protocol and wrote the first draft of the manuscript. Author MA managed the literature searches and together with authors MAOM, MSL and JMG reviewed the manuscript. All authors read and approved the final manuscript.

Article Information

DOI: 10.9734/BJMMR/2016/29512

Editor(s):

(1) Yinhua Yu, Department of Gynecology, Obstetrics and Gynecology Hospital of Fudan University, Shanghai Key Laboratory of Female Reproductive Endocrine Related Diseases, China.

Reviewers:

(1) Prasad Usha, Andhra Medical College, Visakhapatnam, India.

(2) Raheela Mohsin, The Aga Khan University, Stadium Road, Karachi, Pakistan.
Complete Peer review History: <http://www.sciencedomain.org/review-history/16870>

Opinion Article

Received 15th September 2016
Accepted 2nd November 2016
Published 10th November 2016

ABSTRACT

Historically, the creation of a neovagina with an inert prosthesis or synthetic mold and a split-thickness skin graft (McIndoe's technique) has been the most common surgical procedure. The major inconvenient of this technique are those related with: 1) Making the skin graft and the permanent scar in the donor area; and 2) The prostheses used as mold; the material might be of certain weight and stiffness that can produce bedsores on the recto-vaginal septum or necrosis of the lowest portion of the urethra and hypospadias. To avoid the skin graft, currently, good results have been achieved by simply covering the prosthesis with Interceed®. And regarding the neovaginal prostheses, we have designed a new prototype of prosthesis anatomically adapted to

*Corresponding author: E-mail: acien@umh.es;

the vagina of normal women and besides being lightweight, and designed with 3D technology it is made of polylactic acid (PLA, biodegradable polymer derived from lactic acid) that contributes to the epithelialisation of the vagina, and which has been patented and presented in 2nd International Meeting on Rokitansky syndrome (Warsaw, Poland, 26-28 May 2016). The main advantages of the modification of the McIndoe's technique include: 1) The neovagina might be done without skin graft, ie, using only the PLA prosthesis and a biocompatible and biodegradable mesh (used as biogenerative scaffold), thus allowing an almost outpatient surgery, more easy, without further dermal scarring and providing women more comfort and functionality. And 2) Instead 8-9 days of admission to make cures at donor skin graft area, the patient can go home the next day. The McIndoe surgical procedure might then be the most appropriate, simplest and with best anatomical, sexual and psychological results of the surgical techniques for neovagina.

Keywords: *Vaginal agenesis; MRKH syndrome; Rokitansky syndrome; neovaginal prosthesis; neovaginal mold; Polylactic acid (PLA); McIndoe technique.*

ABBREVIATIONS

CAIS : *Complete Androgen Insensitivity Syndrome.*

MRKH : *Mayer-Rokitansky-Kuster-Hauser*

PLA : *Polylactic Acid.*

1. INTRODUCTION

Although currently vaginal dilation is proposed as the first choice treatment, the majority of patients with Mayer-Rokitansky-Kuster-Hauser (MRKH) or Rokitansky syndrome (and cases with CAIS) may require a vaginoplasty [1]. It is also necessary to make vaginoplasty in patients with vaginal or cervico-vaginal atresia with a functional uterus before performing an utero-neovaginal anastomosis. In any case, the aim of vaginoplasty is the formation of a satisfactory vagina in appearance, function, and feeling without additional morbidity [2].

Historically, the creation of a neovagina with an inert prosthesis or synthetic mold and a split-thickness skin graft (McIndoe's technique) has been the most common surgical procedure [2-5]. Other methods for lining of the neovaginal space use a section of intestine, whether free jejunal autograft [6], ileo or sigmoid colon [7]. The intestinal vaginoplasty is not only a major operation but can also lead to excessive foul-smelling vaginal discharge and diversion colitis [8]. In the Davydou technique patient's pelvic peritoneum is used for lining the neovagina [9]; and the use of a human amnion graft is another way of vaginoplasty [10]. The risks of these last techniques are mainly the infection risk of the amnion graft and that the Davydou technique requires laparotomy. Another surgical technique, frequently used in Europe, is the laparoscopic Vecchietti procedure [11] modified by Brucker

and Wallwiener [12,13]. It is a method that provides a neovagina by gradual stretching of the patient's own vaginal introitus skin through traction of a segment ("olive") of a pluggable segmented dummy (a type of vaginal dilator). The modification of Brucker and Wallwiener using vagino-abdominal blunt perforation without vesicorectal tunnelling reduces the time and surgical complications [12]. Other procedures for the creation of the neovagina include the Creatsas vaginoplasty (where neovagina is created with the labia majora and thus without the participation of the elevator muscles, Williams method) [14], and the Wharton-Sheares-George neovaginoplasty [15-17] without skin graft. Buccal or vesical mucosa, autologous *In vitro* cultured tissue from vaginal vestibule and others tissues for lining the neovagina have also been used.

However, we believe that in general, but especially when an utero-neovaginal anastomosis is needed, the best technique for neovagina is the McIndoe procedure. But this method of skin graft lining may be associated with scars (permanent scar at graft donor area – thigh, buttock or abdomen-), graft failure, strictures and contractures of the neovagina in addition to other surgical complications [18]. Another major inconvenient of the McIndoe's technique is related with the prostheses used as mold; many are not properly anatomically designed, are of artisanal fabrication and the material might be of certain weight and stiffness that can produce bedsores on the recto-vaginal septum or necrosis of the lowest portion of the urethra and hypospadias. Solving or improving both aspects, skin graft and prosthesis used, the McIndoe technique might be the most appropriated, simple and with better anatomical and functional results.

- To avoid the skin graft, currently, good results have been achieved by simply covering the prosthesis with Interceed® [19-21]. And following the Wharton-Sheares-George technique, without skin graft, good functional results have been communicated [15-17]. Also Marzieh et al. [22] have obtained good results, with evidence of squamous epithelization of the neovaginal vault, using no grafts in the McIndoe operation. These last authors [22] explain this neovaginal epithelization through the immature squamous metaplasia that results from the proliferation of pluripotential subcolumnar reserve cells, but as it happens during normal vagina embryology [23] it is more likely to occur due to epidermization from the urogenital sinus that in the adult woman is the vaginal introitus. Thus, the epithelization of the vagina seems possible using no grafts, or as suggested by us [24] the use of a Polylactic Acid (PLA) mesh as biogenerative scaffold could also achieve good results.
- A significant reduction in the proximal diameter to remain at introitus and lower third of the vagina (13x3.8→2 cms).
- An anterior recess of the lower half for urethral protection.
- Minimum weight, hollow, drainage hole at both ends and somehow shorter than the previous model prosthesis but that still protrudes slightly in the vulva.
- Hole at the lower end allowing passage of extraction cord.
- Associated to an adaptable and removable plate at its outer end with 4 holes for fastening tapes or fixing belt. and
- The adaptable plate allows vertical positioning of the prosthesis for coating with mesh and/or skin graft, prior to their introduction and placement in neovagina.

Both the prosthesis body and plate have been fabricated with PLA (polylactic acid), a material that has been chosen due to its biocompatibility and stimulation of epithelial regeneration properties [32-37]. As a phantom to be used as maintenance, same prostheses covered with silicon has been prepared (chosen material due to its biocompatibility, smooth and antiadherent characteristics). Thus, the designed PLA prosthesis is prepared to be used for the surgical technique and postoperatively while the coated silicone version would be easier to be self-placed at daily home use. A recent modification of the prototype substitutes the hole for extraction cord for a groove that allows extraction with the removable plate.

The construction of neovagina using prosthesis involves use of vaginal mold which can be designed in various shapes by using different materials, such as silicon [25], foam rubber, wood, plastic, glass, Teflon, Dexon, vacuum expandable condom [26], a simple syringe [27,28], or a polyethylene bag [29]. We have used a Dexon prosthesis of 14x4 cm [30] (see Fig. 1A). However, this Dexon prosthesis is a bit long, of equal diameter at bottom and entrance and slightly heavy and in some cases has caused decubitus injury on the urethra provoking light hypospadias. Therefore, it was interesting to find a lighter and better adaptable prosthesis that considered the dimensions of the normal vagina, both in the fundus and the introitus.

Our modification of McIndoe technique is summarized as follows:

Ación et al. [31] have designed a new prototype of prosthesis anatomically adapted to the vagina of normal women and besides being lightweight, it has been designed with 3D technology and made of PLA (biodegradable polymer derived from lactic acid) that contributes to the epithelialisation of the vagina, and which has been patented and presented in 2nd International Meeting on MRKH syndrome (Warsaw, Poland, 26-28 May 2016).

- Antibiotic prophylaxis and general or spinal anesthesia.
- Opening and neovaginal blunt dissection of the space between the urethra-bladder in front and the rectal wall behind till the bottom at Douglas.
- Coverage of the PLA prosthesis with Interceed (or PLA mesh) (see Fig. 2).
- Introduction of the prosthesis covered with mesh in the neovaginal space, eventually fixing it. Placement of Foley catheter.
- At 24-48 hours, hospital discharge. No removal of the prosthesis for permanent use.
- Control after 8-10 days, removal of the PLA prosthesis, assessment of evolution and self-placement of the coated silicone version. At first it must be carried on all day, then only at night.

The basic and novel features of this new prototype of prosthesis of PLA for neovagina are given below: (see Fig. 1B, 1C):

- Controls every 2-4 weeks to 5-6 months. Then the vagina should be perfectly epithelialized.

The main advantages of the modification of the technique include:

- The neovagina might be done without skin graft; and
- Instead 8-9 days of admission, the patient can go home in 1-2 days.

Acién et al. [31] have suggested that this new prototype prosthesis of PLA adapts perfectly to the length and diameter required in women to perform neovagina. It is rigid but light, with

protection for urethral area and other soft tissues, allowing the muscles of the pelvic floor and vulva to maintain the prosthesis in situ even without external clamping (see Fig. 3). Thus, the design allows that the neovagina (following a modified McIndoe technique) might be done without skin graft, ie, using only the prosthesis of PLA, or associated with a possible PLA mesh [38,39], or with Interceed© (both used as biogenerative scaffold), allowing an easier almost outpatient surgery, without further dermal scarring and providing women with more comfort and functionality. The McIndoe surgical procedure might then be the most appropriate, simplest and with best anatomical, sexual and psychological results of the surgical techniques for neovagina.




Fig. 1. A. Former Dexon prosthesis of 14x4 cms used by our group [30]. B. (1) First prosthesis model designed with 3D technology as a modification of the Dexon one and produced with a 3D PLA printer. (2) Modification of previous model. C. Final PLA prosthesis prototype of 13x3.8 cms. It is 2 cms thinner at the inferior portion, to be placed at introitum




Fig. 2. A. PLA prosthesis with adaptable plate that allows a vertical position during surgery. B. PLA prosthesis covered with Interceed® before being introduced in the neovaginal space

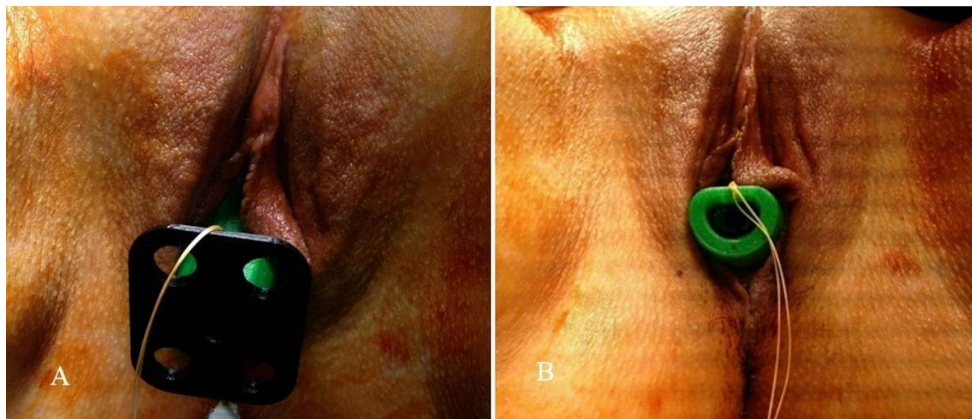


Fig. 3. PLA prosthesis introduced in the neovagina protruding at introitus (A), without the fixing plate (B). (with patient consent)

2. CONCLUSION

Using this new neovaginal prosthesis of PLA and Interceed® mesh, the McIndoe operation might be performed without skin graft favoring that this procedure becomes the most appropriate and with the best functional results of the surgical techniques for neovagina.

ETHICAL APPROVAL

The authors have obtained the Institutional Ethical Approval from the Ethical Committee of Clinical Research “CEIC Hospital General Universitario San Juan de Alicante”.

COMPETING INTERESTS

Authors have declared that no competing interests exist.

REFERENCES

1. Ismail-Pratt IS, Bikoo M, Liao LM, Conway GS, Creighton SM. Normalization of the vagina by dilator treatment alone in Complete Androgen Insensitivity Syndrome and Mayer-Kokitansky-Kuster-Hauser syndrome. *Hum Reprod.* 2007;22: 2020-2024.
2. Klingele CJ, Gebhart JB, Croak AJ, DiMarco CS, Lesnick TG, Lee RA.

- McIndoe procedure for vaginal agenesis: Long-term outcome and effect on quality of life. *Am J Obstet Gynecol.* 2003;189:1569-73.
3. McIndoe A. The treatment of congenital absence and obliterative conditions of the vagina. *Br J Plast Surg.* 1950;2:254-67.
 4. Garcia J, Jones HW. The split thickness graft technic for vaginal agenesis. *Obstet Gynecol.* 1977;49:328-32.
 5. Karapinar OS, Özkan M, Okyay AG Şahin H, Dolapçioğlu KS. Evaluation of vaginal agenesis treated with the modified mcindoe technique: A retrospective study. *J Turk Ger Gynecol Assoc.* 2016;17:101-5
 6. Sakurai H¹, Nozaki M, Sasaki K, Nakazawa H. The use of free jejunal autograft for the treatment of vaginal agenesis: surgical methods and long-term results. *Br J Plast Surg.* 2000;53(4):319-23.
 7. Yang B, Wang N, Zhang S, Wang M. Vaginal reconstruction with sigmoid colon in patients with congenital absence of vagina and menses retention: A report of treatment experience in 22 young women. *Int Urogynecol J.* 2013;24(1):155-60.
 8. Ismail IS, Cutner AS, Creighton SM. Laparoscopic vaginoplasty: Alternative techniques in vaginal reconstruction. *BJOG.* 2006;113(3):340-3.
 9. Marques H de S, dos Santos FL, Lopes-Costa PV, dos Santos AR, da Silva BB. Creation of a neovagina in patients with rokitansky syndrome using peritoneum from the pouch of Douglas: An analysis of 48 cases. *Fertil Steril.* 2008;90(3):827-32.
 10. Dhall K. Amnion graft for treatment of congenital absence of the vagina. *Br J Obstet Gynaecol.* 1984;91(3):279-82.
 11. Borruto F, Chasen ST, Chervenak FA, Fedele L. The Vecchietti procedure for surgical treatment of vaginal agenesis: comparison of laparoscopy and laparotomy. *Int J Gynaecol Obstet.* 1999; 64(2):153-8.
 12. Brucker SY, Gegusch M, Zubke W, Rall K, Gauwerky JF, Wallwiener D. Neovagina creation in vaginal agenesis: Development of a new laparoscopic Vecchietti-based procedure and optimized instruments in a prospective comparative interventional study in 101 patients. *Fertil Steril.* 2008; 90(5):1940-52.
 13. Rall K, Schickner MC, Barresi G, Schönfisch B, Wallwiener M, Wallwiener CW, Wallwiener D, Brucker SY. Laparoscopically assisted neovaginoplasty in vaginal agenesis: A long-term outcome study in 240 patients. *J Pediatr Adolesc Gynecol.* 2014;27(6):379-85.
 14. Creatsas G, Deligeorglou E, Christopoulos P. Creation of a neovagina after creatsas modification of williams vaginoplasty for the treatment of 200 patients with Mayer-Rokitansky-Kuster-Hauser syndrome. *Fertil Steril.* 2010;94(5): 1848-52.
 15. Schätz T, Huber J, Wenzl R. Creation of a neovagina according to Wharton-Sheares-George in patients with Mayer-Rokitansky-Küster-Hauser syndrome. *Fertil Steril.* 2005;83(2):437-41.
 16. Walch K, Kowarik E, Leithner K, Schätz T, Dörfler D, Wenzl R. Functional and anatomic results after creation of a neovagina according to wharton-sheares-george in patients with mayer-rokitansky-küster-hauser syndrome-long-term follow-up. *Fertil Steril.* 2011;96(2):492-497.
 17. Leithner K, Naderer A, Hartung D, Abrahamowicz C, Alexopoulos J, Walch K, Wenzl R, Hilger E. Sexual and psychosocial functioning in women with mrkhs after neovaginoplasty according to wharton-sheares-george: A case control study. *Plos One.* 2015;22;10(4):e0124604.
 18. Templeman CL, Lam AM, Hertweck SP. Surgical management of vaginal agenesis. *Obstet Gynecol Surv.* 1999;54:583-91.
 19. Jackson ND, Roseblatt PL. Use of interceed absorbable adhesion barrier for vaginoplasty. *Obstet Gynecol.* 1994;84: 1048-50.
 20. Motoyama S, Laoag-Fernandez JB, Mochizuki S, Yamabe S, Maruo T. Vaginoplasty with interceed absorbable adhesion barrier for complete squamous epithelization in vaginal agenesis. *Am J Obstet Gynecol.* 2003;188:1260-64.
 21. Inagaki M, Motoyama S, Laoag-Fernandez JB, Yasuda R, Maruo T. Two cases Reports of less invasive surgery using Interceed (oxidized regenerated cellulose) absorbable adhesion barrier for vaginoplasty in Mayer-Rokitansky-Kuster-Hauser syndrome. *Int Surg.* 2009;94:48-53.
 22. Marzieh G, Soodabeh D, Narges I Saghar SS, Sara E. Vaginal reconstruction using no grafts with evidence of squamous epithelialization in neovaginal vault: A simple approach. *J Obstet Gynaecol Res.* 2011;37:195-201.

23. Ación P, Ación MI. Malformations of the female genital tract and embryological bases. *Curr Women's Health Rev.* 2007; 3:248-288.
24. Ación P, Ación MI. Modification and simplification of the mcindoe technique to perform neovagina in patients with vaginal agenesis. In the 2nd International Meeting on MRKH syndrome (Warsaw, Poland); 2016.
25. Coskun A, Coban YK, Vardar MA, Dalay AC. The use of a silicone-coated acrylic vaginal stent in mcindoe vaginoplasty and review of the literature concerning silicone-based vaginal stents: A case report. *BMC Surgery.* 2007;10(7):13.
26. Bhatena HM. The vacuum expandable condom mold for reconstruction of vagina. *Plast Reconstr Surg.* 2006;115:973.
27. Mishra B, Janavar G, Pradeep Y Singh AK, Kumar V, Upadhyay DN. Indigenous technique of fabricating vaginal mould for vaginal reconstruction and uterine drainage in McIndoe vaginoplasty using 10 ml syringe. *Indian J Plast Surg.* 2016; 49:76–80.
28. Ellabban MG. The use of a simple syringe as a stent for McIndoe vaginal reconstruction. *Plast Reconstr Surg.* 2004; 114:622-3.
29. Ozek C, Gurler T, Alper M Gundogan H, Bilkay U, Songur E, Akin Y, Cagdas A. Modified mcindoe procedure for vaginal agenesis. *Ann Plast Surg.* 1999;43:393-6.
30. Acien P. *Treaty of obstetrics and gynecology. II. Gynecology (Spanish). Cap 18: Malformations of the female genital tract.* Ediciones Molloy, Alicante. 2004; 691-739.
31. Ación P, Sánchez-Lozano M, Oliva MA, Ación MI, Martínez-García J. A new model of prosthesis designed as mold to perform neovagina in patients with vaginal agenesis. In the 2nd International Meeting on MRKH syndrome (Warsaw, Poland); 2016.
32. Tayrac R, Chentouf S, Garreau H Braud C, Guiraud I, Boudeville P, Vert M. *In Vitro* degradation and *In vivo* biocompatibility of poly (lactic acid) mesh for soft tissue reinforcement in vaginal surgery. *J Biomed Mater Res part B: Appl Biomater.* 2008; 85B:529-36.
33. Li RY, Liu ZG, Liu HQ, Chen L, Liu JF, Pan YH. Evaluation of biocompatibility and toxicity of biodegradable poly (DL-lactic acid) films. *Am J Transl Res.* 2015;7:1357-70.
34. Hart DR, Fabi SG, White WM, Fitzgerald R, Goldman MP. Current concepts in the use of PLLA: Clinical synergy noted with combined use of microfocused ultrasound and poly-L-lactic acid on the face, neck, and décolletage. *Plast Reconstr Surg.* 2015;136(5 suppl):180-7s.
35. Tyler B, Gullotti D, Mangraviti A, Utsuki T, Brem H. Polylactic acid (PLA) controlled delivery carriers for biomedical applications. *Adv Drug Deliv Rev;* 2016. Available:<http://dx.doi.org/> DOI: 10.1016/j.addr.2016.06.018
36. Saini P, Arora M, Kumar MN. Poly(lactic acid) blends in biomedical applications. *Adv Drug Deliv Rev;* 2016. Available:<http://dx.doi.org/> DOI: 10.1016/j.addr.2016.06.014
37. Roman S, Mangir N, Bissoli J Chapple CR, MacNeil S. Biodegradable scaffolds designed to mimic fascia-like properties for the treatment of pelvic organ prolapse and stress urinary incontinence. *J Biomater Appl.* 2016;30:1578-88.
38. Ozpolat B, Gunal N, Pekcan Z Ayva ES, Bozdogan O, Gunaydin S, Dural K, et al. Polylactic acid and polyethylene glycol prevent surgical adhesions. *Bratisl Lek Listy.* 2016;117:54-8
39. Roman S, Urbánková I, Callewaert G, Lesage F, Hillary C, Osman NI, Chapple CR, Deprest J, MacNeil S, et al. Evaluating alternative materials for the treatment of stress urinary incontinence and pelvic organ prolapse: A comparison of the *In vivo* response to meshes implanted in rabbits. *J Urol.* 2016;196:261-9.

© 2016 Ación et al.; This is an Open Access article distributed under the terms of the Creative Commons Attribution License (<http://creativecommons.org/licenses/by/4.0>), which permits unrestricted use, distribution, and reproduction in any medium, provided the original work is properly cited.

Peer-review history:
The peer review history for this paper can be accessed here:
<http://sciencedomain.org/review-history/16870>