

## Adult-type granulosa cell tumour of the testis: Report of a case and review of the literature

Osama Al-Alao, Tawiz Gul, Ammar Al-Ani, Issam A. Bozom & Khalid Al-Jalham

To cite this article: Osama Al-Alao, Tawiz Gul, Ammar Al-Ani, Issam A. Bozom & Khalid Al-Jalham (2016) Adult-type granulosa cell tumour of the testis: Report of a case and review of the literature, Arab Journal of Urology, 14:1, 44-49, DOI: [10.1016/j.aju.2015.12.002](https://doi.org/10.1016/j.aju.2015.12.002)

To link to this article: <https://doi.org/10.1016/j.aju.2015.12.002>



© 2016 Arab Association of Urology



Published online: 05 Apr 2019.



Submit your article to this journal [↗](#)




Article views: 314



View related articles [↗](#)



View Crossmark data [↗](#)



ONCOLOGY/RECONSTRUCTION  
MINI-REVIEW

# Adult-type granulosa cell tumour of the testis: Report of a case and review of the literature



Osama Al-Alao <sup>a,\*</sup>, Tawiz Gul <sup>a</sup>, Ammar Al-Ani <sup>a</sup>, Issam A. Bozom <sup>b</sup>,  
Khalid Al-Jalham <sup>a</sup>

<sup>a</sup> Urology Department, Hamad General Hospital, Hamad Medical Corporation, Doha, Qatar

<sup>b</sup> Histopathology Section, Laboratory Medicine and Pathology Department, Hamad General Hospital, Hamad Medical Corporation, Doha, Qatar

Received 17 October 2015, Received in revised form 20 December 2015, Accepted 26 December 2015

Available online 6 February 2016

## KEYWORDS

Granulosa;  
Tumour;  
Testis;  
Cord-stromal;  
Adult-type granulosa  
cell tumour

## ABBREVIATIONS

GCT, granulosa cell  
tumour;  
AGCTT, adult-type  
GCT of the testis;  
T2WI, T2 weighted  
imaging;  
CD, cluster of  
differentiation

**Abstract** Granulosa cell tumours (GCTs) can be either juvenile or adult type, and more commonly occur in the ovaries. Adult-type GCTs of the testis (AGCTT) are very rare and only 46 cases have previously been reported. We report here on a 48-year-old Filipino man with a left testicular AGCTT, which measured  $1.2 \times 1.2 \times 1.0$  cm. He underwent radical orchidectomy with postoperative surveillance for 1 year, which included computed tomography with oral intravenous contrast and clinical examinations, which have been unremarkable. The previously reported AGCTTs were briefly reviewed.

© 2016 Arab Association of Urology. Production and hosting by Elsevier B.V. This is an open access article under the CC BY-NC-ND license (<http://creativecommons.org/licenses/by-nc-nd/4.0/>).

\* Corresponding author at: Urology Department, Hamad General Hospital, Hamad Medical Corporation, PO Box 3050, Doha, Qatar. Tel.: +974 66347678.

E-mail address: [osama.alalao@gmail.com](mailto:osama.alalao@gmail.com) (O. Al-Alao).

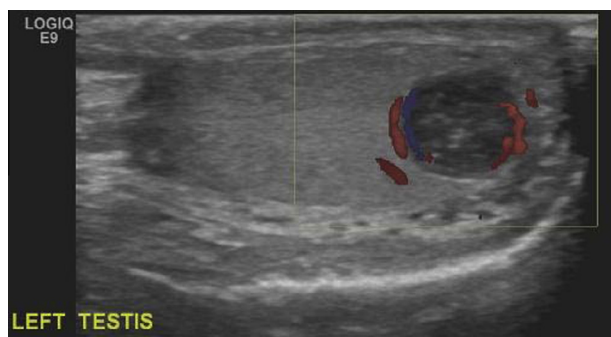
Peer review under responsibility of Arab Association of Urology.



Production and hosting by Elsevier

## Background

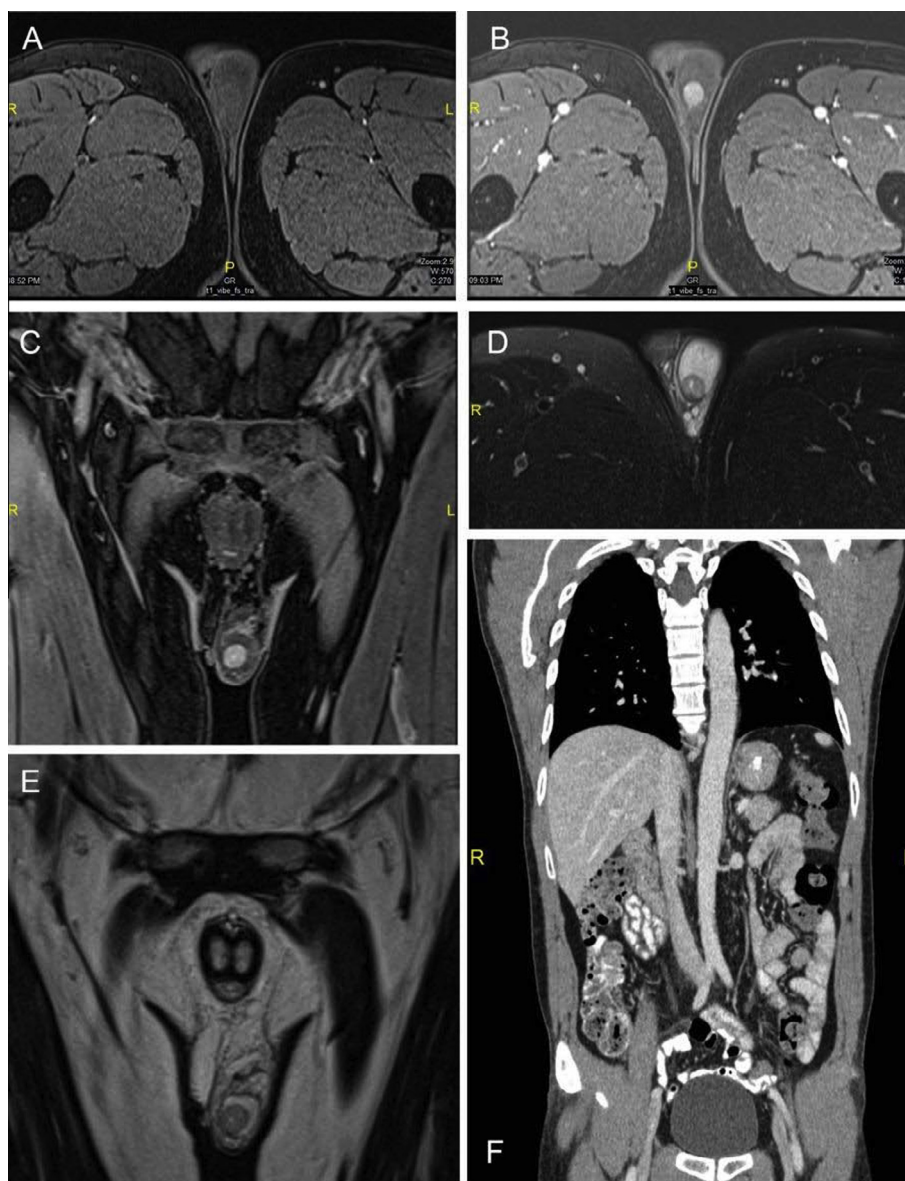Sex cord-stromal tumours of the gonads are numerous including thecomas, fibromas, Sertoli, Leydig, Sertoli-Leydig cell, and granulosa cell tumours (GCTs) [1]. GCTs are divided into two different types: juvenile and adult [2]. The juvenile type commonly occurs in



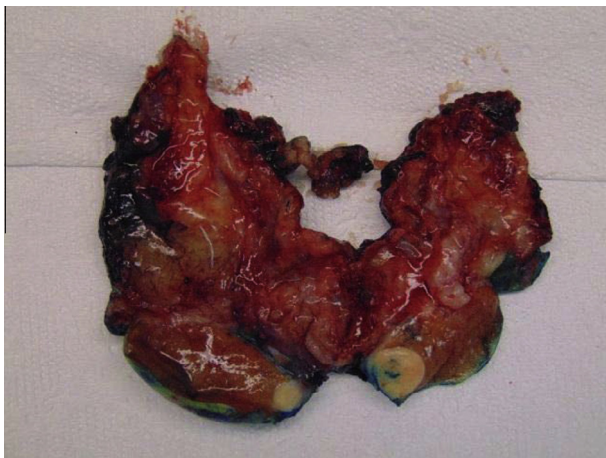
**Figure 1** Left testicular US image with colour flow.

the first 6 months of life [3]. The adult type is very rare and can occur at any time after puberty. Only 46 cases of adult-type GCT of the testis (AGCTT) have been reported to date [1–36]. Many morphological, clinical, and immunohistochemical characteristics have been identified that help in the diagnosis of AGCTT.

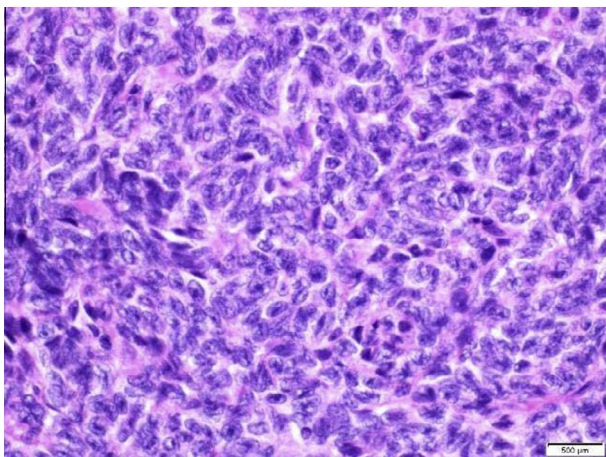
AGCTT presents clinically as a slow, painless enlargement over a variable period of time in > 50% of cases [4–6]. The mean (range) age at diagnosis is 47 (12–77) years [4,7]. Erectile dysfunction, gynecomastia, and decreased libido may also be present [5,7]. AGCTTs typically have a solid, well-circumscribed, lobular mass



**Figure 2** MRI showing: A, T1 pre-contrast showing left testicular lesion; B, T1 post-contrast showing left testicular lesion; C, T1 coronal section post-contrast showing left testicular lesion; D, axial section T2 fat suppression; E, T2 coronal section; F, coronal section by multi-planar reconstruction showing no lymph nodes enlarged in the retroperitoneal space.



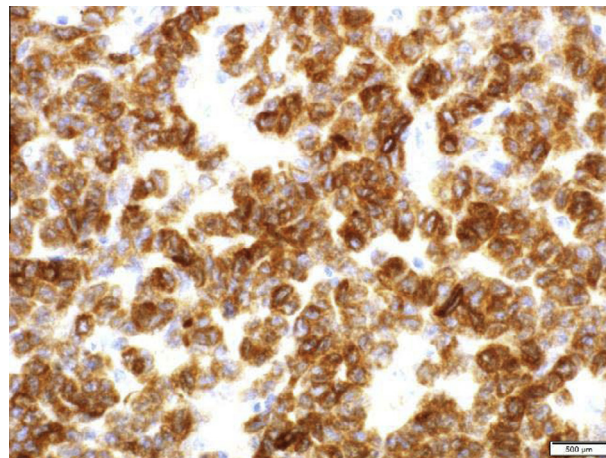
**Figure 3** A testicular lower pole well-circumscribed solid mass measuring  $1.2 \times 1.2 \times 1.0$  cm. It is fleshy and has a homogenous cut surface.



**Figure 4** A microscopic section shows elongated tumour cells with scanty cytoplasm and pale ovoid nuclei. The nuclei show longitudinal grooves giving them a coffee bean-like appearance.

that may have a fibrous pseudocapsule in gross morphological analysis.

Some AGCTTs have the potential for distant metastases and thus poor outcomes, but otherwise they are non-functioning, slow growing, and most often benign [4,8]. A relatively long survival period was found in patients with metastases to regional lymph nodes; however, deaths occurring at few months to a few years after metastases have occurred in patients that have distant metastasis and who exhibited rapid disease progression [8]. The retroperitoneal lymph nodes are the most common metastatic region, but lung, liver, and bone metastases have also been reported [8–10]. Recent evidence indicates that  $\approx 20\%$  of cases of AGCTT are malignant; however, factors predictive of malignancy have yet to be well defined due to the very limited number of cases.



**Figure 5** The tumour cells are strongly positive for inhibin.

### Case report

A 48-year-old man presented with the complaint of mild pain in his left testis. He denied dysuria, urethral discharge, back pain, abdominal pain, or recent illness. There was no personal or family history of genitourinary disease and his past medical history was not significant. There had been no previous abdominal or genitourinary surgeries and he was a non-smoker. His vital signs were within normal limits and a physical examination was remarkable for tenderness and swelling in the left testis, with a small hard mass at the lower pole on palpation of the left testicle, and the right testicle was unremarkable. Other pertinent findings included the absence of cervical, supraclavicular, or inguinal lymphadenopathy, gynecomastia, urethral discharge, or scrotal swelling. Abdominal examination revealed no masses or tenderness.

Urine analysis showed no red blood corpuscles, leucocytes, or protein, and was negative for nitrite and leucocyte esterase. Serum tumour markers included lactate dehydrogenase measuring 197 IU/L, serum  $\alpha_1$ -fetoprotein measuring 2 ng/mL, and plasma  $\beta$  human chorionic gonadotrophin measuring  $< 0.50$  IU/mL. Testicular ultrasonography (US) revealed a left testis measuring  $3.9 \times 1.4$  cm with a cystic lesion of  $1.2 \times 1.2 \times 1.0$  cm towards its lower pole, with coarse internal echoes, and the wall showed mild irregularity (Fig. 1).

Contrast-enhanced MRI of the pelvis revealed a well-defined left intra-testicular focal lesion ( $1.2 \times 1.2 \times 1.0$  cm) at the inferio-posterior aspect of the testis, which had a low signal on T2 weighted imaging (T2WI), and low to iso-intense on T1WI. There was a central high signal on T2WI, suggestive of fluid (necrosis). The tunica albuginea was infiltrated in a small area in the posterior aspect of the lesion to the near-by epididymis (Fig. 2).

**Table 1** The morphological and clinical data of the cases reported to date of AGCTT. Modified from Schubert et al. [35].

Case	Age, years	Testis	Signs and duration, years	Endocrine symptoms	Size, cm	Follow-up, years	Source
1	35	Right	15	Gynaecomastia	9	8.5 NED	Laskowski [14]
2	21	Left	Incidental	Gynaecomastia	Microscopic	Autopsy finding	Cohen and Diamond [15]
3	53	Right	1	Gynaecomastia	> 10	NS	Massachusetts General Hospital [16]
4	52	Right	5	None	13	NS	Melicow [17]
5	41	Left	8	Gynaecomastia	10.1	0.42 DOD	Mostofi et al. [18]
6	53	Right	2	Gynaecomastia	10	17 NED	Marshall et al. [19]
7	44	Right	Few months	None	3.5	3 NED	Talerman [20]
8	41	Right	NS	None	1.8	NS	Gaylis et al. [21]
9	83	Left	NS	None	NS	DOC	Düe et al. [22]
10	61	Right	0.17	None	5	2 NED	Nistal et al. [23]
11	26	Left	0.58	Gynaecomastia	10	14 NED	Matoska et al. [12]
12	NS	NS	NS	NS	NS	NS	Sasano et al. [24]
13	42	Left	NS	None	NS	AWD	Monobe and Manabe [25]
14	57	Right	10	None	2.5	3 years DOC	Jimenez-Quintero et al. [11]
15	55	Left	Not known	None	1.3	NS	Jimenez-Quintero et al. [11]
16	60	Left	Many years	None	7	11.17 DOD	Jimenez-Quintero et al. [11]
17	39	Left	2	None	4	3 NED	Jimenez-Quintero et al. [11]
18	16	Left	Incidental	None	1.8	0.33 NED	Jimenez-Quintero et al. [11]
19	29	Right	Incidental	None	7.5	1.17 AWD	Jimenez-Quintero et al. [11]
20	76	Left	Incidental	None	0.7	0.08 NED	Jimenez-Quintero et al. [11]
21	NS	NS	NS	NS	NS	NS	Renshaw et al. [26]
22	NS	NS	NS	NS	NS	NS	Renshaw et al. [26]
23	NS	NS	NS	NS	NS	NS	Renshaw et al. [26]
24	NS	NS	NS	NS	NS	NS	Renshaw et al. [26]
25	NS	NS	NS	NS	NS	NS	Renshaw et al. [26]
26	NS	NS	NS	NS	NS	NS	Renshaw et al. [26]
27	51	Left	0.17	Incidental	7	1.08 NED	Morgan and Brame [27]
28	48	Right	3	None	5	0.58 NED	Al-Bozom et al. [28]
29	54	Left	Incidental	None	NS	NS	Wang et al. [29]
30	33	NS	Incidental	None	1	NS	Guzzo et al. [30]
31	51	Left	Incidental	None	NS	6 AWD	Suppiah et al. [9]
32	59	Left	2	None	15	4 NED	Hisano et al. [31]
33	32	Left	Incidental	None	1.98	NS	Arzola et al. [32]
34	77	Left	Incidental	None	4	NS	López [33]
35	45	Right	Months	None	6.5	2 NED	Ditonno et al. [6]
36	12	Left	5	None	10	NS	Gupta et al. [4]
37	55	NS	Lung metastases	None	NS	NS	Hammerich et al. [8]
38	28	Left	Incidental	None	2.6	NS	Song et al. [34]
39	21	Left	Incidental	None	1	2 NED	Hanson and Ambaye [5]
40	77	Right	NS	NS	2.5	NS	Lima et al. [1]
41	22	Left	NS	NS	1	NS	Lima et al. [1]
42	40	Left	NS	NS	2.1	NS	Lima et al. [1]
43	78	Left	Incidental	None	13	1.92 NED	Schubert et al. [35]
44	37	Left	Incidental	None	4.2	2 NED	Miliaras et al. [2]
45	22	Left	0.75	None	4.6	NS	Tanner et al. [36]
46	48	Left	0.25	None	2	1 NED	Present case

NS, not specified; NED, no evidence of disease; DOD, dead of disease; AWD, alive with disease; DOC, death from other cause.

The patient agreed to an orchidectomy after his initial diagnosis and a radical orchidectomy was performed with no complications.

Gross appearance of the specimen revealed a testis with a lower pole well-circumscribed solid mass measuring  $1.2 \times 1.2 \times 1.0$  cm. The mass had a fleshy and homogenous cut surface (Fig. 3). Microscopic evaluation revealed an encapsulated well-circumscribed nodule consisting of micro follicles, cords and solid

sheets of tumour cells. The cells appeared elongated with scanty cytoplasm and pale ovoid nuclei. The nuclei had longitudinal grooves giving them a coffee bean-like appearance (Fig. 4). Very few mitotic figures could be seen. There was no evidence of haemorrhage, necrosis, sarcomatous differentiation or other germ cell elements.

Immunohistochemistry was applied, the tumour cells were strongly positive for vimentin, inhibin (Fig. 5),

calretenin, and cluster of differentiation 99 (CD99). Focal staining for smooth muscle actin, desmin, and cytokeratin (AE1/AE3) was seen. The tumour cells were negative for placental alkaline phosphatase, stem cell marker Oct-3/4, Sal-like protein 4, synaptophysin, chromogranin, and CD117.

Given the histopathological findings, as well as the immunohistochemistry, the patient was diagnosed with AGCTT. The 1-year postoperative surveillance, including CT with oral i.v. contrast and clinical examinations, has been unremarkable.

## Discussion

The adult-type GCT is extremely rare in the testis, Schubert et al. [35] have found 43 cases in the literature [1–36] and we were able to find three more recent cases in PubMed (Table 1) [2,36]. However, in most of the reports these tumours are only the object of immunohistochemical or cytogenetic investigations; thus, the clinical data are missing partially [5,11,22,24]. The initial treatment for all reported cases was radical or inguinal orchidectomy [11,8]. There is no evidence to support additional therapy in patients with a disease clinically confined to the testicle. Dissection of the retroperitoneal lymph nodes should be considered with pathology suggestive of malignant features or if small-volume metastatic disease is present. If performed, it should be immediately after the orchidectomy. A very poor prognosis is expected for patients with unresectable metastatic, widespread disease [6]. There is no consensus about the treatment for metastatic disease, which may include chemotherapy [11,8] and/or radiation therapy [12]. In the reported cases of AGCTT, three were treated with chemotherapy. One received cisplatin and doxorubicin 121 months after initial diagnosis and died from disease 13 months later. The next was treated with retroperitoneal lymph node dissection followed by one cycle of etoposide, had a recurrence treated with radical inguinal lymphadenectomy and radiation therapy; and was alive 2 months after the last therapy. The last patient received six cycles of BEP (bleomycin, etoposide, cisplatin) followed by metastasectomy of the right lung and was alive at 39 months after initial diagnosis. Interestingly, Harrison et al. [13] reported an advanced AGCTT partially responding to an angiogenesis inhibitor after initially resisting cytotoxic chemotherapy. Their patient enrolled in a phase I study of pazopanib (GW-786034, GlaxoSmithKline), an oral multi-targeted receptor tyrosine kinase inhibitor of vascular endothelial growth factor receptor-1, -2, and -3; platelet-derived growth factor receptor- $\beta$ ; and c-kit. He was treated at the recommended phase II dose (800 mg by mouth daily) and tolerated this therapy well, and  $\approx$ 32 months after his initial diagnosis the patient died from his disease.

Jimenez-Quintero et al. [11] suggested that haemorrhage, a necrosis size of  $> 7.0$  cm, and presence of lymphovascular invasion, might be indicative of malignancy because these characteristics were present in the malignant cases they identified. In a recent attempt to find variables for malignancy prediction, Hanson and Ambaye [5] evaluated laterality, patient age, presence of gynaecomastia, presence of mitoses, necrosis, and tumour size. Of the variables analysed, only a tumour size of  $> 5.0$  cm showed statistical significance.

US of the abdomen and testis, coupled with clinical examination, may be sufficient in cases thought to have low malignant potential [11]. More extensive follow-up may be warranted with larger tumours or tumours deemed to be aggressive. A follow-up protocol suggested is an abdominal and testicular US along with chest X-ray, with a CT of the abdomen and pelvis every 6 months. The duration of follow-up is not well-defined; however, long-term follow-up is mandatory because metastasis has been found after 10 years of treatment [6].

## Conclusion

Further reporting every case of AGCTT, to allow thorough analysis, is necessary to identify factors that can reliably predict tumour behaviour and to optimise methods of diagnosis and treatment together with classic means of follow-up.

Long-term follow-up with a sufficient number of cases may be needed to define optimal treatment options for patients with this rare tumour.

## Consent

Written informed consent was obtained from the patient for publication of this case report and accompanying images. A copy of the written consent is available for review by the Editor-in-Chief of this journal.

## Conflicts of interests

The authors declare that they have no competing interests.

## Source of Funding

None.

## References

- [1] Lima JF, Jin L, de Araujo AR, Erikson-Johnson MR, Oliveira TJ, Sebo TJ, et al. FOXL2 mutations in granulosa cell tumors occurring in males. *Arch Pathol Lab Med* 2012;136:825–8.
- [2] Miliaras D, Anagnostou E, Moysides I. Adult type granulosa cell tumor: a very rare case of sex-cord tumor of the testis with review of the literature. *Case Rep Pathol* 2013;2013:932086, <<http://www.hindawi.com/journals/crpa/2013/932086/>>. Accessed December 2015.

- [3] Couture J, Bolduc S. A rare testicular solid mass in children: juvenile granulosa cell tumor of the testis. *Can Urol Assoc J* 2012;**6**, E101-3.
- [4] Gupta A, Mathur SK, Reddy CP, Arora B. Testicular granulosa cell tumor, adult type. *Indian J Pathol Microbiol* 2008;**51**:405-6.
- [5] Hanson JA, Ambaye AB. Adult testicular granulosa cell tumor: a review of the literature for clinicopathologic predictors of malignancy. *Arch Pathol Lab Med* 2011;**135**:143-6.
- [6] Ditunno P, Lucarelli G, Battaglia M, Mancini V, Palazzo S, Trabucco S, et al. Testicular granulosa cell of the adult type: a new case and review of the literature. *Urol Oncol* 2007;**125**:322-5.
- [7] Norman RW, Sheridan-Jonah A, Merrimen J, Gupta R. Adult granulosa cell tumor of the testicle. *Can J Urol* 2013;**20**:6640-2.
- [8] Hammerich KH, Hille S, Ayala GE, Wheeler TM, Engers R, Ackermann R, et al. Malignant advanced granulosa cell tumor of the adult testis: case report and review of the literature. *Hum Pathol* 2008;**39**:701-9.
- [9] Suppiah A, Musa MM, Morgan DR, North AD. Adult granulosa cell tumour of the testis and bony metastasis. A report of the first case of granulosa cell tumour of the testicle metastasizing to bone. *Urol Int* 2005;**75**:91-3.
- [10] Colecchia M, Mikuz G, Algaba F. Rare tumors of the testis and mesothelial proliferation of the tunica vaginalis. *Tumori* 2012;**98**:270-3.
- [11] Jimenez-Quintero LP, Ro JY, Zavala-Pompa A, Amin MB, Tetu NG, Ordoñez NG, et al. Granulosa cell tumor of the adult testis: a clinicopathologic study of seven cases and a review of the literature. *Hum Pathol* 1993;**24**:1120-5.
- [12] Matoska J, Ondrus D, Talerman A. Malignant granulosa cell tumor of the testis associated with gynecomastia and long survival. *Cancer* 1992;**69**:1769-72.
- [13] Harrison MR, Huang W, Liu G, Gee J. Response to antiangiogenesis therapy in a patient with advanced adult-type testicular granulosa cell tumor. *Oncology (Williston Park)* 2009;**23**:792-5.
- [14] Laskowski J. Feminizing tumor of the testis: general review with case report of granulosa cell tumor of the testis. *Endokrynol Pol* 1952;**3**:337-43.
- [15] Cohen J, Diamond J. Leontiasis ossea, slipped epiphyses and granulosa cell tumor of the testis with renal disease: report of a case with autopsy findings. *Arch Pathol* 1953;**56**:488-500.
- [16] Massachusetts General Hospital. Case records of the Massachusetts General Hospital: weekly clinicopathological exercises: case No. 41471. *New Engl J Med* 1955;**253**:926-31.
- [17] Melicow MM. Classification of tumors of the testis: a clinical pathological study based on 105 primary and 13 secondary cases in adults and 3 primary and 4 secondary cases in children. *J Urol* 1955;**73**:547-74.
- [18] Mostofi FK, Theiss EA, Ashley DJ. Tumors of the specialized gonadal stroma in human male patients: androblastoma, Sertoli cell tumor, granulosa theca cell tumors of the testis, and gonadal stromal tumor. *Cancer* 1959;**12**:944-57.
- [19] Marshall FF, Kerr Jr WS, Kliman B, Scully RE. Sex cord-stromal (gonadal stromal) tumors of the testis: a report of 5 cases. *J Urol* 1977;**117**:180-4.
- [20] Talerman A. Pure granulosa cell tumour of the testis. Report of a case and review of the literature. *Appl Pathol* 1985;**3**:117-22.
- [21] Gaylis FD, August C, Yeldandi A, Nemcek A, Garnett J. Granulosa cell tumor of the adult testis: ultrastructural and ultrasonographic characteristics. *J Urol* 1989;**141**:126-7.
- [22] Düe W, Dieckmann KP, Niedobitek G, Bornhöft G, Loy V, Stein H. Testicular sex cord stromal tumour with granulosa cell differentiation: detection of steroid hormone receptors as a possible basis for tumour development and therapeutic management. *J Clin Pathol* 1990;**43**:732-7.
- [23] Nistal M, Lazaro R, Garcia J, Paniagua R. Testicular granulosa cell tumors of the adult type. *Arch Pathol Lab Med* 1992;**16**:284-7.
- [24] Sasano H, Nakashima N, Matsuzaki O, Kato H, Aizawa S, Sasano N, et al. Testicular sex cord-stromal lesions: immunohistochemical analysis of cytokeratin, vimentin and steroidogenic enzymes. *Virchows Arch A Pathol Anat Histopathol* 1992;**421**:163-9.
- [25] Monobe Y, Manabe T. Malignant sex-cord stromal tumor of the testis: report of a case with special reference to its unusual intracytoplasmic substructures. *Jpn J Clin Oncol* 1992;**22**:414-20.
- [26] Renshaw AA, Gordon M, Corless CL. Immunohistochemistry of unclassified sex cord-stromal tumors of the testis with a predominance of spindle cells. *Mod Pathol* 1997;**10**:693-700.
- [27] Morgan DR, Brame KG. Granulosa cell tumour of the testis displaying immunoreactivity for inhibin. *BJU Int* 1999;**83**:731-2.
- [28] Al-Bozom IA, El-Faqih SR, Hassan SH, El-Tiraifi AE, Talic RF. Granulosa cell tumor of the adult type: a case report and review of the literature of a very rare testicular tumor. *Arch Pathol Lab Med* 2000;**124**:1525-8.
- [29] Wang BY, Rabinowitz DS, Granato Sr RC, Unger PD. Gonadal tumor with granulosa cell tumor features in an adult testis. *Ann Diagn Pathol* 2002;**6**:56-60.
- [30] Guzzo T, Gerstein M, Mydlo JH. Granulosa cell tumor of the contralateral testis in a man with a history of cryptorchism. *Urol Int* 2004;**72**:85-7.
- [31] Hisano M, Souza FM, Malheiros DM, Pompeo AC, Lucon AM. Granulosa cell tumor of the adult testis: report of a case and review of the literature. *Clinics (Sao Paulo)* 2006;**61**:77-8.
- [32] Arzola J, Hutton RL, Baughman SM, Mora RV. Adult-type testicular granulosa cell tumor: case report and review of the literature. *Urology* 2006;**68**, 1121.e13-6.
- [33] López JJ. Adult-type granulosa cell tumor of the testis. Report of a case. *Tumori* 2007;**93**:223-4.
- [34] Song Z, Vaughn DJ, Bing Z. Adult type granulosa cell tumor in adult testis: report of a case and review of the literature. *Rare Tumors* 2011;**3**:e37.
- [35] Schubert TE, Stoehr R, Hartmann A, Schöne S, Löbelenz M, Mikuz G. Adult type granulosa cell tumor of the testis with a heterologous sarcomatous component: case report and review of the literature. *Diagn Pathol* 2014;**9**:107.
- [36] Tanner SB, Morilla DB, Schaber JD. A case of adult granulosa cell tumor of the testis. *Am J Case Rep* 2014;**15**:471-5.