



Unilateral Foot Drop by Bilateral Ganglion Cysts: An Imaging Approach to Diagnosis

**Aakanksha Agarwal¹, Abhishek Chandra^{2*}, Naresh Mangalhari¹,
Rajendra Prasad Assat² and Ramesh Chandra Meena²**

¹Department of Radiodiagnosis, SMS Medical College, Jaipur, Rajasthan, India.

²Department of Orthopaedics, SMS Medical College, Jaipur, Rajasthan, India.

Authors' contributions

This work was carried out in collaboration among all authors. Authors AC and AA designed the study, wrote the protocol and wrote the first draft of the manuscript. Author NM edited the manuscript and was the consultant radiologist in the case while author RPA was the primary operating surgeon. Author RCM managed the literature searches. All authors read and approved the final manuscript.

Article Information

DOI: 10.9734/AJMAH/2019/v14i330101

Editor(s):

- (1) Dr. Ikem, Innocent Chiedu, Professor, Department of Orthopaedic Surgery and Traumatology, Obafemi Awolowo University, Ile-Ife Nigeria.
- (2) Dr. Parth Trivedi, Lecturer, C. M. Patel College of Physiotherapy, Civil Hospital Campus, Sector-12, Gandhinagar, Gujarat, India.
- (3) Dr. Nicolas Padilla- Raygoza, Professor, Department of Nursing and Obstetrics, Division of Health Sciences and Engineering, Campus Celaya-Salvatierra, University of Guanajuato, Mexico.

Reviewers:

- (1) Xing Wu, Tongji University, China.
- (2) Ronit Wollstein, New York University, USA.
- (3) Mohit Kumar Patralekh, GGS IP University, India.
- (4) Vijaya Krishnan, India.

Complete Peer review History: <http://www.sdiarticle3.com/review-history/47012>

Case Study

Received 19 November 2018

Accepted 28 February 2019

Published 13 March 2019

ABSTRACT

Ganglion cysts are pseudocysts with no epithelial lining of their own. These are non-neoplastic lesions filled with gelatinous material and originate from tendon sheath, ligament, bursa, joint capsule or subchondral bone. Rarely, they may present in an intramuscular location, away from the joint with no synovial communication. Upper limb involvement is more common and such lesions are usually found on the hand, wrist and ankle. Despite their common occurrence, peripheral nerve compression due to these cysts is rare with cases of ulnar and median nerve compressions infrequently reported in the literature. In lower limb, dorsal surface of the foot is reported to be the most common site. Occurrence of ganglion cysts in lower limb causing compressive neuropathy is an even rarer combination. We report a case with unilateral common peroneal nerve palsy with incidentally detected bilateral intramuscular ganglion cysts. Even an extensive literature search did

*Corresponding author: Email: abhishekchandra.dr@gmail.com;

not reveal any such case report. The patient underwent high resolution ultrasound imaging for the possible cause of compression of common peroneal nerve. Incidentally, cystic lesions were identified in the intramuscular plane causing nerve compression in the right leg with similar lesions at the same location in the left leg. On the left side, patient was free of neuropathic symptoms as the nerve was seen passing between the cystic lesions, not getting compressed. The patient then underwent MR imaging with contrast and intramuscular ganglion was kept as the provisional diagnosis of the cystic lesion. Operative management was planned to relieve the compressive neuropathy and excision biopsy of the lesion proved it to be a ganglion cyst.

Keywords: Foot drop; common peroneal nerve palsy; imaging findings; intermuscular ganglion cysts.

1. INTRODUCTION

Ganglion cysts are the most common tumours of the upper limb [1-5] with no definite aetiology. These cysts have no true epithelial lining and are filled with gelatinous material comprising mainly of hyaluronic acid, possibly occurring due to degenerative and local chronic inflammatory changes. Ganglia rarely result in compressive neuropathy of the peripheral nerves and have an uncommon occurrence in the lower limb [6,7,8]. We present a rare case of a middle-aged Asian female with unilateral foot drop who was incidentally diagnosed as having bilateral intramuscular ganglion cysts causing common peroneal nerve compression. This was an uncommon location of a common benign tumour presenting with uncommon symptoms of nerve compression, which in itself is very rare [9]. Literature review revealed quite a few reports on ganglion cysts causing foot drop, but to the best of our knowledge, there is no case report of bilateral ganglion cysts causing unilateral foot drop with an imaging-based approach to diagnosis. This case report demonstrates the use of high resolution ultrasound and MR in diagnosis and explains how one nerve was spared in spite of bilateral occurrence of the cysts.

2. CASE REPORT

A middle-aged Asian female presented with right lower limb weakness and foot drop which was gradual in onset. She had complaint of burning pain in right lower limb for the past three months and visible swelling in the anterolateral part of the proximal right leg. On examination she had weakness of tibialis anterior and peroneus longus with lump in the proximal part of anterolateral aspect of the right leg Fig. 1. The swelling was soft, partially compressible with restricted mobility. Positive tinell's sign could be elicited by tapping the swelling. Gentle tapping over the neck of fibula elicited mild pain and a

tingling sensation which radiated towards the toes. Incidentally, a similar swelling was also observed on the contralateral leg at the same site. Based on clinical symptoms and examination, common peroneal nerve palsy was kept as a provisional diagnosis. The patient then underwent imaging studies for the possible cause of common peroneal nerve compression [10]. Findings at high resolution ultrasound were suggestive of multi-loculated anechoic cystic lesion with posterior acoustic enhancement distal to the level of neck of fibula lying in the intramuscular compartment of the right leg. The common peroneal nerve was hypoechoic with loss of normal fascicular architecture and was noted to lie stretched over the cystic lesion Fig. 2. The contralateral leg showed similar cystic lesions which were found to be more numerous but the common peroneal nerve was seen lying between the cystic lesions. The patient then underwent MRI with contrast for proper characterisation of the cystic lesion and to look for communication with joint.

MR imaging of right leg depicted a well-defined multi-loculated lesion which was hyperintense on T2 Fig. 3 and isointense to muscle on T1 weighted image with a thin rim of peri-lesional fat. The lesion measured 42*31*18 mm, lying just anterior and inferior to neck of fibula between the tibialis anterior, extensor digitorum longus and peroneus longus with extension into the tibialis anterior. The common peroneal nerve was hyperintense at level of lateral tibial condyle and noted to pass over the cystic lesion on distal tracing on proton density sequence. Peri-lesional high signal intensity in tibialis anterior, extensor digitorum longus and peroneus longus on T2 weighted and PD sequence suggestive of peri-lesional oedema was noted with streaky hyperintensities on T1 weighted image suggesting fatty infiltration. These findings imply muscle denervation secondary to common peroneal nerve compression by ganglion cyst. Post contrast images depicted thin rim

enhancement of the lesion with no internal vascularity suggesting cystic nature of the lesion Fig. 4. No joint extension was found on cranial tracing of the lesion. Diffusion weighted image showed no diffusion restriction with corresponding ADC fall.

Contralateral leg MR imaging corroborated ultrasound findings depicting a similar lesion of size 50*26*19 mm. As the common peroneal nerve was traversing through the lesion on left side, it helped in the salvation of nerve from compressing effect of cyst. Imaging diagnosis of bilateral ganglion cysts in muscle plane with common peroneal nerve compression on right side was made.

The patient underwent surgical resection of the cyst in the symptomatic leg under spinal anaesthesia and excisional biopsy confirmed the imaging diagnosis. Excision was done by an oblique incision over the anterolateral region of fibular head. The common peroneal nerve was identified and safeguarded. Blunt dissection was done with longitudinal splitting between tibialis anterior and extensor digitorum longus. The cystic lesion was identified and removed en-masse with surrounding tumour bed excision to ensure complete removal to prevent recurrence. The common peroneal nerve was identified and was noted to be intact intra-operatively Fig. 5. The lesion was a multi-loculated cyst with thick gelatinous fluid. The post-operative period was uneventful and the patient was discharged on

antibiotics. At 1 month follow up, patient had substantial improvement in pain and heaviness of the legs. Her foot drop gradually improved to near normal with physical rehabilitation over a period of 3 months.

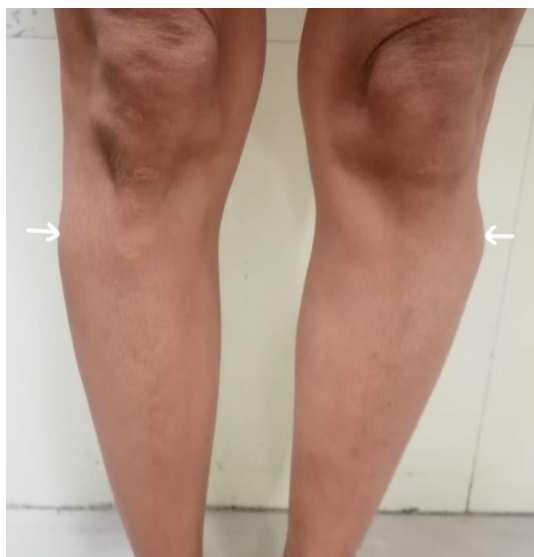

Fig. 1. Clinical image of the patient showing swelling in anterolateral compartments of both legs. The swelling was soft in consistency, compressible with restricted mobility

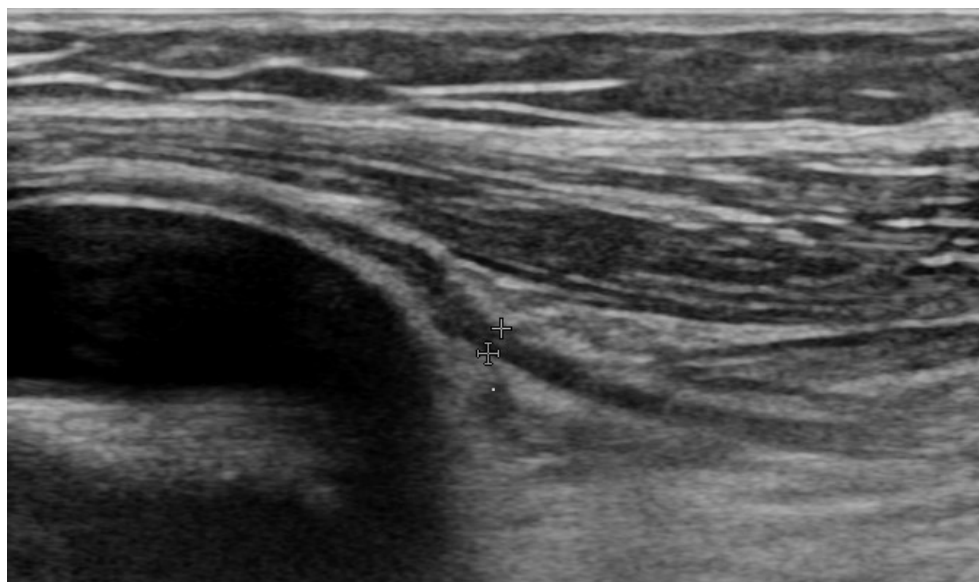


Fig. 2. High resolution ultrasound image showing common peroneal nerve (arrowheads) lying stretched over the underlying cystic lesion

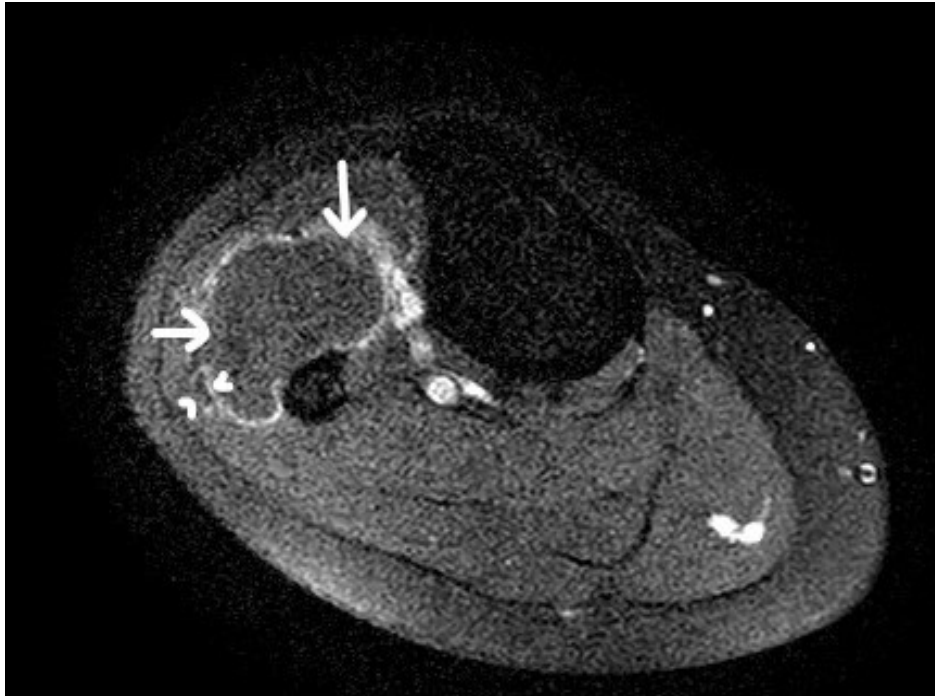


Fig. 3. T1 weighted fat saturated post contrast image shows enhancing cyst walls with no internal enhancement (arrow) suggestive of cystic nature of the lesion. Also seen is enhancement of the sheath of the common peroneal nerve (arrowhead) lying in close proximity to the cyst

Histopathological examination of the cystic lesion confirmed clinic-radiological diagnosis of intramuscular ganglion cyst.

3. DISCUSSION

Common peroneal nerve is one of the two terminal branches of sciatic nerve which originates at the level of distal femur and enters the lateral compartment of leg where it winds around neck of fibula, lying deep to the peroneus longus muscle. This is the most common site of common peroneal nerve involvement which may be post traumatic, compressive or due to entrapment [11].

As the nerve is superficial in the proximal leg, blunt trauma and fibular neck fractures are a common cause of common peroneal neuropathy. Compressive neuropathy due to ganglion cysts is however a rare occurrence. Evaluation of neuropathic symptoms begins with clinical examination and is aided by electrodiagnostic and imaging studies. Clinical examination reveals weakness of dorsiflexors and evertors of foot - tibialis anterior and peronei muscles respectively. Imaging is a relatively new modality of

investigation and includes high resolution ultrasound which helps in anatomical delineation of the nerve with identification of the possible cause of neuropathy, which in this case was due to stretch of the nerve over the ganglion cysts. MR imaging helps in characterisation of the lesion, assessment of joint status and muscle denervation. High resolution ultrasound imaging is a quick, cost effective and reliable method to identify neuropathies, which can be confirmed on MRI and co-related with clinical scenario. The differential diagnosis that were considered in this case were ganglion cysts, myxoma, peripheral nerve sheath tumour (PNST) and synovial cyst. The clear cystic nature of the lesion was confirmed on ultrasound and MRI, thus ruling out myxoma which is hypoechoic on grey scale with some degree of internal enhancement on contrast imaging. The nerve was identified to be separate from the lesion on high resolution ultrasound which was also confirmed on MRI, excluding PNST. Synovial cysts have joint communication which was not present as confirmed by cranial tracing of the lesion on MRI. [10] Thus, a provisional diagnosis of ganglion cyst in muscular plane involving the lateral compartment of leg was made.

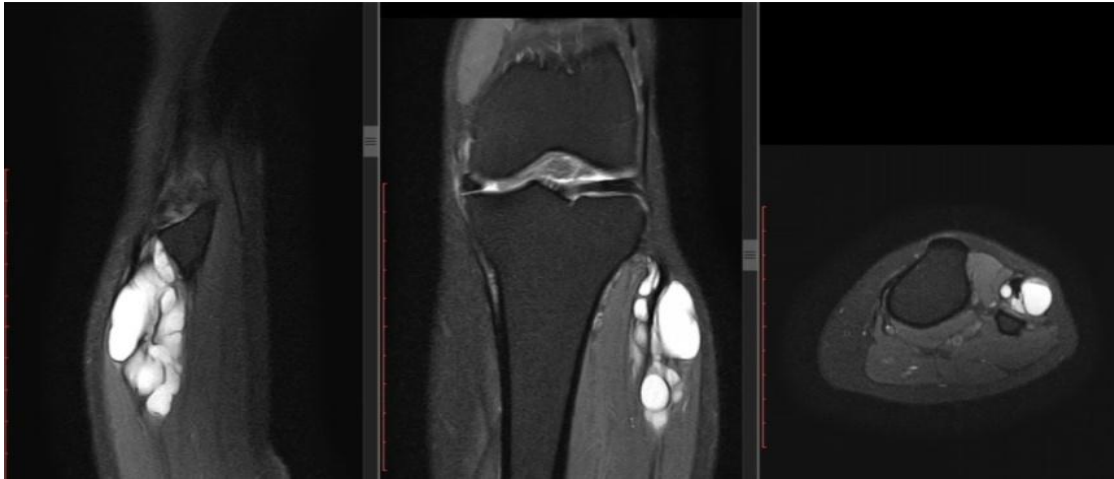

Fig. 4. Sagittal, coronal and axial T2 weighted MR images showing multiloculated cystic lesion at level of the neck of fibula, lying in the muscular plane with no communication to the joint

Indication of surgery in our case was to relieve symptoms due to nerve compression. Intra-operatively it is necessary to remove the complete bulk of tumour with surrounding normal soft tissue excision in order to ensure complete removal of the cyst with its coverings to prevent recurrence. Excisional biopsy is deemed necessary to confirm diagnosis and to rule out any chances of malignancy. The contralateral leg had similar ganglion cysts but as the nerve was passing between the cystic lesions, the patient did not have any complaints in the left leg. On follow up after 6 months, the patient has significant relief in pain and has partially regained her motor power.

With this case report, we demonstrate a rare cause of common peroneal neuropathy due to an

uncommon location of a very common benign tumour which was diagnosed using high resolution ultrasound. The cysts were present bilaterally but unilateral symptoms were explained by ultrasound and MRI which showed stretch of only the right sided nerve while the left one was spared as it traversed between the cystic locules. Literature search revealed case reports [12,13,14] on common peroneal nerve palsy due to ganglion cysts but none of them had an imaging approach to diagnosis. The reported cases were of unilateral compression of the nerve, while bi-laterality of cysts with unilateral symptoms make our report unique. We also report the advantage of using imaging in diagnosis of peripheral neuropathy.

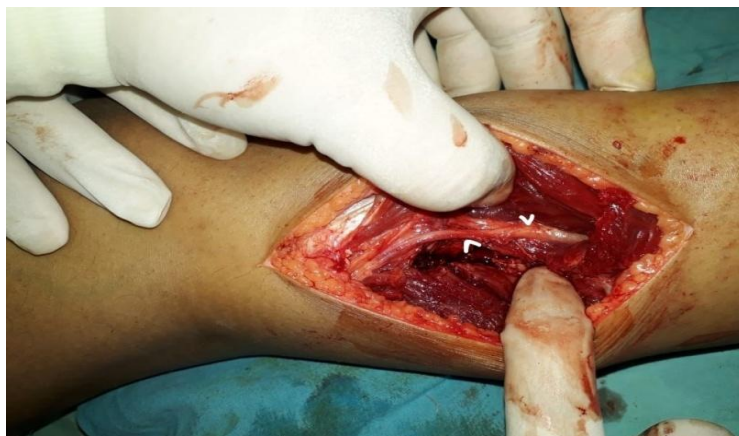

Fig. 5. Intra-operative picture showing intact common peroneal nerve (arrowheads) after excision of the cyst

4. CONCLUSION

Ganglion cysts should be kept as a differential diagnosis in similar clinical scenarios and appropriate imaging and histopathological correlation is necessary for the final diagnosis. High resolution ultrasound and MRI can be reliably used for diagnosis of peripheral neuropathies, similar to this case.

CONSENT AND ETHICAL APPROVAL

Patient consent and ethical approval was taken prior to submission of the report.

ACKNOWLEDGEMENT

We would like to thank Dr. Usha Jaipal, Head of the Department of department of Radiodiagnosis for her guidance and support.

COMPETING INTERESTS

Authors have declared that no competing interests exist.

REFERENCES

1. Gül M, Özkaya U, Parmaksızoğlu A, Sökücüve S, Kabukçuoğlu Y. Drop foot case caused by a ganglion cyst. Fieh Tip Bülten. 2008;42(4).
2. Rozbruch SR, Chang V, Bohne WH, Deland JT. Ganglion cysts of the lower extremity: An analysis of 54 cases and review of the literature. Orthopedics. 1998;21(2):141–148.
3. Kerrigan JJ, Bertoni JM, Jaeger SH. Ganglion cysts and carpal tunnel syndrome. J Hand Surg Am. 1988;13(5): 763-5
4. Sultan C. Ganglion der Nervenscheide des Nervus Peroneus. Zentralblatt für Chirurgie. 1921;48:963–5.
5. Soren A. Pathogenesis and treatment of ganglion. Clin Orthop Relat Res. 1966;48: 173-179.
6. Pontious J, Good J, Maxian SH: Ganglions of the foot and ankle. A retrospective analysis of 63 procedures. J Am Podiatr Med Assoc. 1999;89(4):163–168.
7. Thornburg LE. Ganglions of the hand and wrist. J Am Acad Orthop Surg. 1999;7: 231-238.
8. Beaman FD, Peterson JJ. MR imaging of cysts, ganglia, and bursae about the knee. Radiol Clin North Am. 2007;45:969-982.
9. Garland H, Moorhouse D. Compressive lesions of the external popliteal (common peroneal). nerve. Br Med J 1952;2(4799): 1373–8.
10. Wu JS, Hochman MG. Soft-tissue tumors and tumorlike lesions: A systematic imaging approach. Radiology. 2009; 253(2):297–316.
11. Sunderland S, Ray LJ. The intraneural topography of the sciatic nerve and its popliteal divisions in man. Brain. 1948; 71(Pt. 3):242–73.
12. Schmidt I. Common peroneal nerve palsy caused by an initially misdiagnosed extraneural and intraneural benign ganglion cyst of the peroneal nerve in a 11-year-old child: A rare but severe condition. Int J Case Rep Images. 2017; 8(9):623–626
13. Dimitrios Nikolopoulos, George Safos, Neoptolemos Sergides, Petros Safos. Deep Peroneal Nerve Palsy Caused by an Extraneural Ganglion Cyst: A rare case. Case Reports in Orthopedics; 2015. Article ID 861697, 4 pages. Available:https://doi.org/10.1155/2015/861 697
14. Kukreja MM, Telang VG. Common Peroneal nerve palsy secondary to a proximal Tibiofibular Joint “Ganglion Cyst”—A case report and review of literature. Open Journal of Orthopedics. 2015;5:369-377.

© 2019 Agarwal et al.; This is an Open Access article distributed under the terms of the Creative Commons Attribution License (<http://creativecommons.org/licenses/by/4.0>), which permits unrestricted use, distribution, and reproduction in any medium, provided the original work is properly cited.

Peer-review history:
The peer review history for this paper can be accessed here:
<http://www.sdiarticle3.com/review-history/47012>