

Thoracic Syringomyelia in a Patient with Amyotrophic Lateral Sclerosis

Daniele Lo Coco^{1,2}, Rossella Spataro², Alfonsa Claudia Taiello²
and Vincenzo La Bella^{2*}

¹Neurology Unit, Civic General Hospital ARNAS, 90127, Palermo, Italy.

²Department of Experimental Biomedicine and Clinical Neurosciences, ALS Clinical Research Center, University of Palermo, Via G. La Loggia 1, 90129 Palermo, Italy.

Authors' contributions

This work was carried out in collaboration between both authors. Authors DLC and VLB made the diagnosis and outlined the case report. Authors DLC, RS, and ACT managed the literature search and wrote the first draft of the manuscript with assistance from author VLB. All authors read and approved the final manuscript.

Article Information

DOI: 10.9734/IINDJ/2015/17176

Editor(s):

(1) Zhefeng Guo, Department of Neurology, University of California, Los Angeles, USA.

Reviewers:

(1) Mario Ciampolini, Università di Firenze, Department of Pediatrics, Università di Firenze, Italy.

(2) Raghvendra Vijay Ramdasi, Jaslok Hospital & Research Centre, Mumbai India.

Complete Peer review History: <http://www.sciencedomain.org/review-history.php?iid=840&id=29&aid=8665>

Short Communication

Received 1st March 2015
Accepted 20th March 2015
Published 2nd April 2015

ABSTRACT

We report a patient with bulbar-onset, clinically defined, sporadic amyotrophic lateral sclerosis bearing an isolated syringomyelia of the lower thoracic portion of the spinal cord. This is a very unusual association between two rare and progressive disorders, both affecting the spinal motoneurons. Syringomyelia might have acted as a phenotypic modifier in this ALS patient.

Keywords: Amyotrophic lateral sclerosis; syringomyelia; spinal dysraphism; disease progression.

1. INTRODUCTION

Syringomyelia is an uncommon myelopathy characterized by the presence of a cavity in the spinal cord, which is often found in the low

cervical region. This disorder is often associated to a Chiari malformation. Rarely a syringomyelia is induced by trauma, arachnoiditis, or spinal cord tumours.

*Corresponding author: E-mail: vincenzo.labella@unipa.it;

Syringomyelia may produce a clinical picture similar to amyotrophic lateral sclerosis (ALS). However, the slow progression of the disease and the presence of sensory signs, along with the MRI evidence of the syringomyelic cyst generally allow the differential diagnosis.

In this report we describe a patient with sporadic ALS, in whom a thoracic syringomyelia was discovered during the diagnostic workup. We present here evidences that syringomyelia might have influenced the clinical progression.

2. CASE REPORT

The patient is a 49-year-old man who has been working as a truck-driver since he was 23. His past family and medical history were negative for neurological disorders. This patient presented with one-year history of dysarthria and dysphagia, followed by weakness on his right hand, which then extended proximally the whole arm, and then spread to the opposite arm. A few months after presentation, he noticed stiffness in the legs and mild difficulty in walking. He was then referred to our ALS Clinic Research Center.

The neurological examination showed normal cognitive functions. There was jaw jerk, fasciculations in the tongue, spastic dysarthria and dysphagia for liquids and solid food. The optical fundus was normal. There was a moderate atrophy of proximal and distal muscles of the upper limbs (right to left), diffuse fasciculations to both upper and lower limbs, and a spastic tetraparesis, prevalent at lower limbs, with bilateral Hoffmann and Babinski signs. Sensory, cerebellar and sphincter functions were normal.

The EMG examination, performed on upper and lower limbs, showed fibrillation potentials, positive waves, fasciculation and reduced recruitment in multiple myotomes of the four limbs. Nerve conduction studies were within the normal range.

The somatosensory-, visual- and auditory-evoked potentials were within the normal range.

The biochemical work-up was negative, including normal serum proteins and immunoglobulins electrophoresis, thyroid and parathyroid hormones, serum electrolytes, antibodies to GM1 and myelin-associated glycoproteins.

MRI of the brain and cervical spinal cord were normal. The MRI of the thoracic spine showed a

4.3 centimeters syrinx between T8 and T10, more evident in T2-weighted images (Fig. 1).

The Medical Research Council (MRC) system was employed to assess strength of deltoid, biceps, triceps, wrist extensor, wrist flexor, finger extensor and finger flexor in the upper limbs; and iliopsoas, quadriceps, hamstrings, ankle dorsiflexion, plantar flexion, and toe extension and flexion in the lower limbs.

The patient's clinical conditions worsened over time, with a rapid progression of his motor deficit and rigidity. At present, he has developed a severe dysarthria and dysphagia associated to sialorrhea, and a moderate dyspnoea. The forced vital capacity has been detected below 50%, with a marked restrictive deficit, but the patient refused the non-invasive mechanical ventilation. Muscle strength is now severely impaired, in particular in the lower limbs, and he is totally dependent on activities of daily living.

3. DISCUSSION

In this report we have described a patient with a sporadic ALS in whom an isolated syringomyelia of the lower portion of the thoracic spinal cord has been detected.

ALS was first suspected on the basis of a clinical concurrence of both upper and lower motoneurons signs, involving the four limbs and the bulbar region. The complete biochemical, electrophysiologic and imaging work-up then allowed the diagnosis of clinically definite ALS, according to the El Escorial-WFN revised criteria [1]. The MRI of the spine revealed a 4.3 cm syrinx which extended longitudinally between T8 and T10 (Fig. 1).

To our knowledge this is the second description of an association between ALS and syringomyelia. In a previous report, in fact, four independent and asymptomatic cervical syringes were revealed at the autopsy in a 59-year-old patient with ALS, who died for respiratory distress [2].

Although the clinical presentation of ALS in our patient and the whole diagnostic work-up ruled out any causal relationship to his thoracic syringomyelia, the evolution of symptoms and muscle strength dysfunction displayed some peculiarities. The motoneuron degeneration spread from the bulbar region down to cervical, thoracic and lumbar regions, but the rate of

decline of muscle strength in lower limbs, as measured by MRC, appeared to be faster than that of the upper limbs. As shown in Fig. 2, in fact, the patient lost an average of 4 MRC points/month in legs as compared to 2 MRC points/month in the arms. Given that in ALS the progressive motor deficit in the upper and lower limbs appears to be linear and symmetric [3-6], we suggest that in our patient the thoracic syringomyelia contributed to the unexpected faster muscle strength decline in the legs. This might be due to a subclinical, syrinx-mediated, damage of the corticospinal tract and lumbar motoneurons. It is known, in fact, that syrinx

cavities can damage α -motoneurons and provoke their isolation from inhibitory interneuronal circuits [7]; these abnormalities can even spread to spinal segments not directly damaged from the syrinx [8].

Repeated clinical evaluations failed to reveal sensory deficit in our patient. Although syringomyelia is normally associated with sensory signs, it is possible that in the patient the relatively small dimensions of his thoracic cavity might have allowed a functional rearrangement of the crossing spino-thalamic fibers in that region.

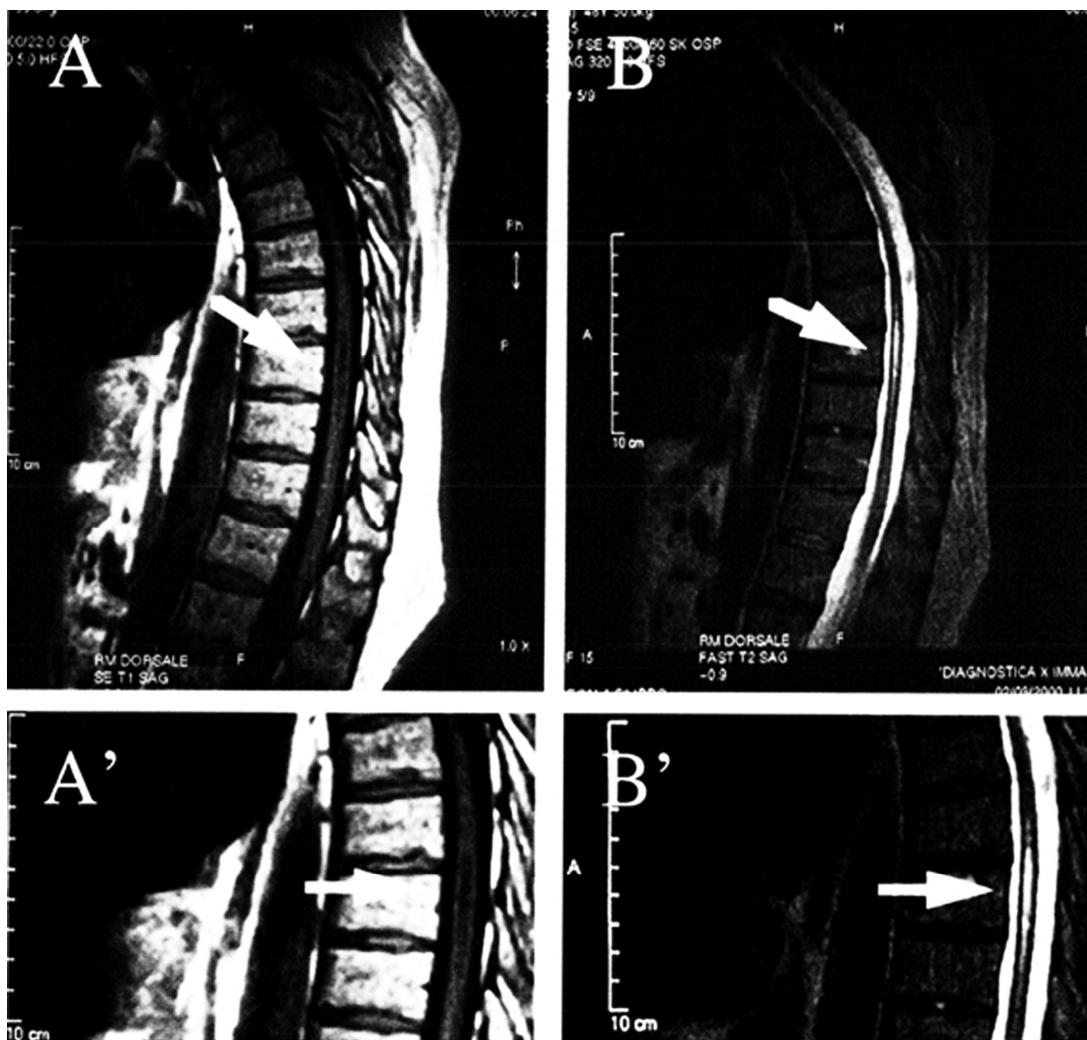
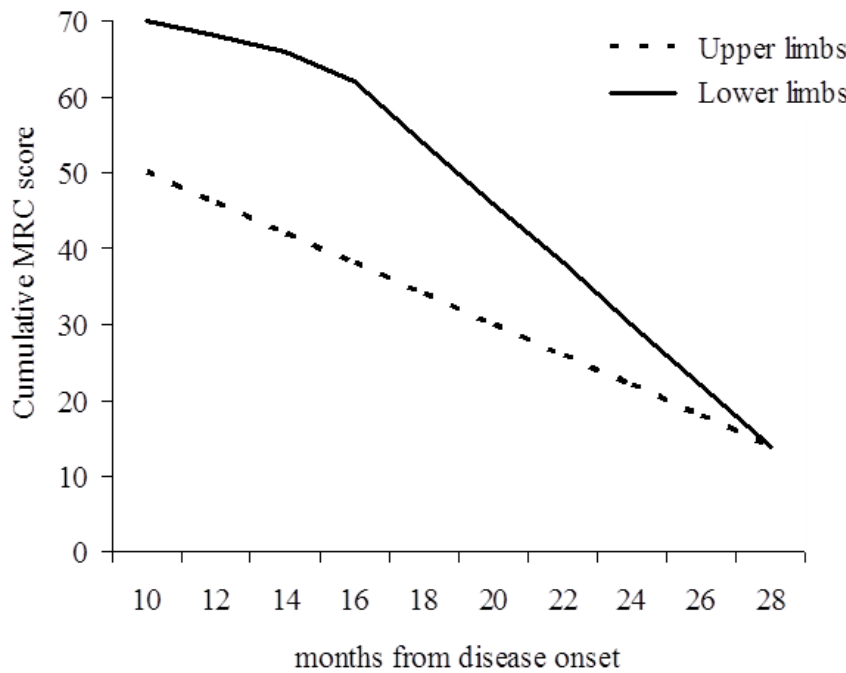


Fig. 1. Thoracic MRI of the patient

(A) T1 and (B) T2-weighted sagittal MRI show a syrinx at the level of T8 - T10 vertebral bodies (arrow). (A') and (B'): the same images at higher magnification



Lo Coco et al, Fig 2

Fig. 2. Average course of muscle strength deterioration in the patient

The muscle strength decline in lower limbs appeared later during the clinical course, and the average rate of deterioration appears to be faster than the upper limbs. a score of 0 points indicates the most severely affected condition, a score of 70 points indicates the normal condition

4. CONCLUSION

In conclusion our findings suggest that a spinal dysraphism, such as syringomyelia, when co-existing with ALS, might affect the progression of this severe neurodegenerative disease. Therefore, although apparently asymptomatic, the syrinx might have acted in our ALS patient as a phenotypic modifier.

CONSENT

All authors declare that 'written informed consent was obtained from the patient (or other approved parties) for publication of this case report and accompanying images.

ETHICAL APPROVAL

It is not applicable.

COMPETING INTERESTS

Authors have declared that no competing interests exist.

REFERENCES

1. Brooks BR, Miller RG, Swash M, Munsat TL. El Escorial revisited: Revised criteria for the diagnosis of amyotrophic lateral sclerosis. *Amyotroph Lateral Scler.* 2000; 1:293-299.
2. AAmada K, Sudih K, Fukaura H, Yanagihara T, Hamada T, Tashiro K, Isu T. An autopsy case of amyotrophic lateral sclerosis associated with cervical syringomyelia. *No to Shinkei.* 1990;2:527-531.
3. Turner MR, Hardiman O, Benatar M, Brooks BR, et al. Controversies and

- priorities in amyotrophic lateral sclerosis. *Lancet Neurol.* 2013;12:310-322.
4. Simon NG, Turner MR, Vucic S, Al-Chalabi A, Shefner J, Lomen-Hoerth C, Kiernan MC. Quantifying disease progression in amyotrophic lateral sclerosis. *Ann Neurol.* 2014;76:643-57.
 5. Brooks BR, Shodis KA, Lewis DH, Rawling JD, Sanjak M, Belden DS, Hakim H, DeTan Y, Gaffney JM. Natural history of amyotrophic lateral sclerosis. Quantification of symptoms, signs, strength, and function. *Adv Neurol.* 1995; 68:163-184.
 6. Balendra R, Jones A, Jivraj N, Knights C, et al. Estimating clinical stage of amyotrophic lateral sclerosis from the ALS functional rating scale. *Amyotroph Lateral Scler Frontotemporal Degener* 2014; 15:279-84.
 7. Nogues MA, Leiguarda RC, Rivero AD, Salvat F, Manes F. Involuntary movements and abnormal spontaneous EMG activity in syringomyelia and syringobulbia. *Neurology.* 1999;52:823-834.
 8. Nogues MA, Stalberg E. Electrodiagnostic findings in syringomyelia. *Muscle Nerve.* 1999;22:1653-1659.

© 2015 Coco et al.; This is an Open Access article distributed under the terms of the Creative Commons Attribution License (<http://creativecommons.org/licenses/by/4.0>), which permits unrestricted use, distribution, and reproduction in any medium, provided the original work is properly cited.

Peer-review history:

The peer review history for this paper can be accessed here:
<http://www.sciencedomain.org/review-history.php?iid=840&id=29&aid=8665>