



Vascular Events during Chemotherapy in Treatment of Germ Cell Testicular Cancer

Ahmed Mahfouz^{1*}, Nahla Mousa², Ashraf Fawzy³, Jassim Al Suwaidi⁴,
Nisrine El Muabby¹ and Shaban Mohammed¹

¹Department of Pharmacy, Heart Hospital, Hamad Medical Corporation, Doha, Qatar.

²Department of Oncology, National Centre for Cancer Care & Research, Hamad Medical Corporation, Doha, Qatar.

³Department of Medicine, Hamad General Hospital, Hamad Medical Corporation, Doha, Qatar.

⁴Department of Cardiology, Heart Hospital, Hamad Medical Corporation, Doha, Qatar.

Authors' contributions

This work was carried out in collaboration between all authors. All authors read and approved the final manuscript.

Article Information

DOI: 10.9734/IJMPCR/2015/20196

Editor(s):

(1) Rafik Karaman, Bioorganic Chemistry, College of Pharmacy, Al-Quds University, Jerusalem, Palestine.

Reviewers:

(1) Anonymous, University of Bari, Bari, Italy.

(2) Muhammad Aslam, Ziauddin University, Karachi, Pakistan.

Complete Peer review History: <http://sciencedomain.org/review-history/10607>

Case Study

Received 16th July 2015
Accepted 30th July 2015
Published 19th August 2015

ABSTRACT

Introduction: We report a case of acute myocardial infarction and acute cerebral infarction during treatment with bleomycin, etoposide, and cisplatin (BEP) regimen for germ cell testicular cancer.

Case Presentation: A 28 year old smoker man diagnosed with germ cell testicular cancer without any history of ischemic heart disease complained of sudden chest pain on day 6 of his second cycle of chemotherapy. His electrocardiogram showed Q waves (Lead V1–V3) and T wave inversion (Lead V1–V3). He underwent primary percutaneous coronary intervention (PCI) to the proximal left artery descending (LAD) lesion (95%) with thrombus aspirated with export catheter and predilated with percutaneous transluminal coronary angioplasty (PTCA) and bar metal stent (BMS) deployed in the LAD.

One week later; the patient developed left sided weakness and ptosis of left eyelid. Magnetic resonance angiography and venography to the head and neck showed total occlusion of left

*Corresponding author: E-mail: amahfouz@hotmail.com;

vertebral artery.

Discussion: Acute MI and cerebral infarction are uncommon in young man without cardiovascular risk factors such as hypertension, diabetes, or dyslipidemia. Thromboembolic events (TEEs) are more likely in our case presented without significant risk factors; which was confirmed in our case by coronary angiography.

Conclusion: Thromboembolic events are adverse events associated with chemotherapy treatment that may need further attention in regard to the initial prevention including pharmacological prophylaxis and possibility of an alternative regimen particularly in patients with testicular germ cell tumor.

Keywords: Cisplatin; germ cell testicular cancer; germ cell tumor; myocardial infarction; cerebral infarction; thromboembolic events.

ABBREVIATIONS

BMS: Bar metal stent; BEP: Bleomycin; etoposide and cisplatin regimen; CT: Computerized tomography; ICU: Intensive care unit; LAD: Left artery descending; LDH: Lactate dehydrogenase; MI: Myocardial infarction; PCI: Percutaneous coronary intervention; PCR: Polymerase chain reaction; PTCA: Percutaneous transluminal coronary angioplasty; TEEs: Thromboembolic events; VTE: Venous thromboembolism.

1. INTRODUCTION

Testicular cancer is the most common solid tumor among men commonly affecting male in age of 15–35 years. It accounts 1% of all cancer in men approximately, 95% of which are germ cell tumor [1].

With the advance in chemo-therapies, cure rate of germ cell tumor with combination chemotherapy is high even disseminated testicular cancer. Systematic randomized trials have shown that bleomycin, etoposide, and cisplatin (BEP) regimen is the main stay of treatment however; such combination chemotherapy has a risk of complication which includes leukemia, therapy related toxicity, infertility, nephrotoxicity, neurotoxicity, pulmonary and vascular toxicity [2].

Thromboembolic events (TEEs) including coronary and cerebral vessels are adverse reactions and a serious complication of chemotherapy. TEEs occurred in a significant number of reported cases who received chemotherapy although there are no pre-existing risk factors for coagulopathy such as atherosclerosis, hypertension, diabetes in these cases [3-6]. TEEs are common in patients with germ cell cancer than other cancer patients and venous events secondary to chemotherapy are usually higher incidence than arterial events [7]. Few cases of acute myocardial infarction (MI) were reported after receiving chemotherapy. The

number of reported cases are very few however, it had been reported that acute MI are strongly associated with 5-Fluorouracil, cisplatin, vinca alkaloids, and BEP regimen [6,8-10].

Cerebral infarction has been also reported in patients after receiving chemotherapy (incidence 0.137%) and cerebral infarction is common with cisplatin-based chemotherapy [11-14].

Cisplatin is commonly associated with increased risk of venous thromboembolism (VTE). The pathogenesis of cisplatin induced thrombogenicity is unclear; however some proposed mechanisms are cisplatin may induce direct endothelial injury, platelet activation, decreased activity of protein C, and up-regulation of prothrombotic factors [13,15].

A recent meta-analysis comparing the risk of VTE in cisplatin vs non-cisplatin based chemotherapy found that the incidence of VTE was 1.92% (95% CI, 1.07% to 2.76%) in patients receiving cisplatin-based chemotherapy versus 0.79% (95% CI, 0.45% to 1.13%) in patients receiving non-cisplatin chemotherapy; the relative risk of VTE for cisplatin vs non-cisplatin-based chemotherapy was 1.67 (95% CI, 1.25 to 2.23, P=0.01) [16].

The incidence of TEEs in a recent retrospective study was 18% specifically in patients with solid tumors receiving cisplatin-based chemotherapy [17].

A routine evaluation of systolic function with echocardiography is important to detect high risk patient for cardiotoxicity prior to chemotherapy administration with a subsequent serial monitoring [18] however; further investigations may help in predicting cardiotoxicity especially for cisplatin containing regimen considering thromboembolic events and diastolic function e.g. stress tests, a computerized tomography (CT) coronary angiogram, and E/A ratio (ratio of peak early to late diastolic filling velocity).

2. CASE PRESENTATION

28 year old Egyptian man is not known to have any ischemic heart disease or any chronic illness, presented to the emergency department with worsened right sided chest pain of 10 days. Chest x-ray (Fig. 1) showed large opacity in right hemithorax and chest CT scan (Fig. 2) showed large anterior mediastinal mass measuring 12.7 X 13 X 13 cm. His laboratory results (Table. 1) revealed an elevation of α -fetoprotein, β -human chorionic gonadotropin, and lactate dehydrogenase.

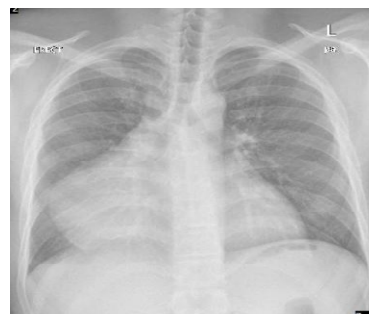


Fig. 1. Chest x-ray

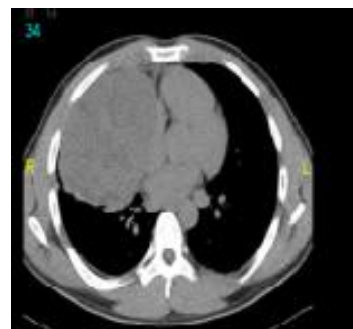

Fig. 2. Chest CT scan

Table 1. Laboratory results

Laboratory test	Result	Unit	Normal range
Hemoglobin	15.2	g/dl	(13 – 17)
Hematocrit	46.4	%	(40 – 50)
White blood cell	12↑	$\times 10^3/\text{ul}$	(4 – 10)
Platelet	230	$\times 10^3/\text{ul}$	(150 – 400)
Sodium	136	mmol/L	(135 – 145)
Potassium	3.6	mmol/L	(3.6 – 5.1)
Magnesium	0.86	mmol/L	(0.65 – 1.05)
Serum creatinine	78	$\mu\text{mol/L}$	(62 – 124)
Total cholesterol	4.04	mmol/L	< 5.17
LDL cholesterol	1.78	mmol/L	3.36
HDL cholesterol	1.33	mmol/L	> 1
Triglyceride	2.02	mmol/L	< 1.7
Protein C chromogenic	89%		70 – 140%
Protein S clotting activity	108.7%		60 – >130%
High sensitive troponin T	12640↑	ng/L	(0 – 14)
Creatine Kinase - MB	332.6 ↑	ng/mL	(< 5)
Alpha-fetoprotein	2416 ↑	IU/mL	(0 – 5)
β human chorionic gonadotropin	110 ↑	IU/L	(0 – 5)
Lactate dehydrogenase	269↑	U/L	(240 – 480)
Epstein Bar Virus Viral Capsid Ag-IgG	Positive		
Epstein Bar Virus Nuclear Antigen	Positive		
Cytomegalovirus IgG	Positive		
Cytomegalovirus IgM	Positive		
Herpes Simplex Virus Type 1 IgM	Positive		
Herpes Simplex Virus Type 2 IgM	Positive		
Herpes Simplex Virus Type 1 IgG	Negative		
Herpes Simplex Virus Type 2 IgG	Negative		

Histopathology result for biopsies (anterior mediastinum) showed mixed germ cell tumor with rhabdomyosarcoma.

He was diagnosed with mixed germ cell tumor of the anterior mediastinum (stage III) and it was decided to treat him with BEP regimen that consists of etoposide 100 mg/m²/day plus cisplatin 20 mg/m² daily for five days with bleomycin 15 mg/m² day 1, day 8, and day 15 the cycle repeated every 3 weeks. The treatment with chemotherapy started and he received the first cycle of BEP (bleomycin-etoposide-cisplatin) regimen without complication. On the day 6 of the second cycle, he complained of sudden chest pain. His electrocardiogram showed Q waves (Lead V1–V3) and T wave inversion (Lead V1–V3) and positive cardiac biomarkers.

He was found to have acute anterolateral myocardial infarction without no electrolyte disturbance or hyperlipidemia. He underwent primary percutaneous coronary intervention (PCI) to the proximal left artery descending (LAD) lesion (95%) with thrombus aspirated with export catheter (Figs. 3 and 4) and predilated with 2.7 X 2 cm balloon (percutaneous transluminal coronary angioplasty) and 3.5 X 24 mm bar metal stent (BMS) deployed in the LAD.

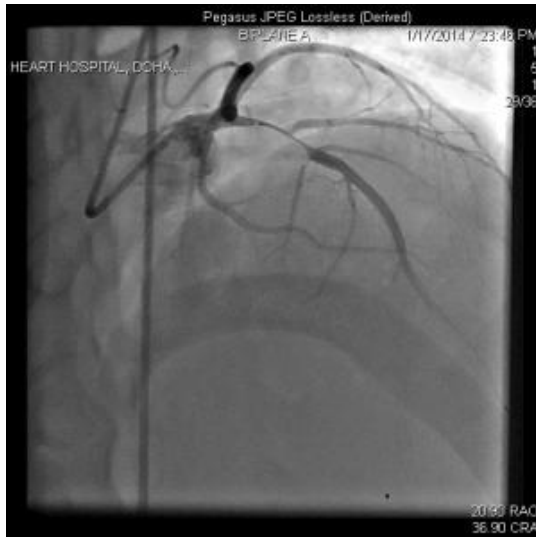

Fig. 3. Pre-Percutaneous coronary intervention (PCI)

One week later, he developed severe headache with left sided weakness and left eyelid ptosis. Magnetic resonance angiography and venography to the head and neck showed total

occlusion of left vertebral artery immediately after its origin with tiny left cerebellar and brain stem lesion.

The case was discussed in thoracic multidisciplinary team meeting for an alternative option of treatment as the patient refused any further chemotherapy. The tumor size is huge to be surgically re-sected or to be irradiated so it is recommended changing the combination chemotherapy with less cardio-toxic medication.

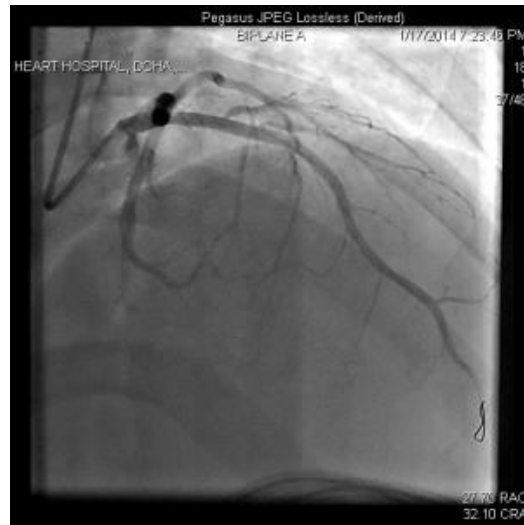

Fig. 4. Post-PCI (Post-angioplasty)

He developed acute respiratory distress syndrome after receiving ifosfamide 1.2g/m² for 5 days, then transferred to the intensive care unit (ICU) requiring a mechanical ventilation with inotropic support and treated empirically with antimicrobial therapy including meropenem, vancomycin, and oseltamivir. Sepsis workup was sent and the result came negative however, H₁N₁ polymerase chain reaction (PCR) and influenza virus A PCR was positive. He developed febrile neutropenia (4 days after the last dose of ifosfamide) and caspofungin was added with granulocyte-colony stimulating factor (GCSF) support. Unfortunately he passed away after staying three weeks without any improvement in ICU with full support.

3. DISCUSSION

Acute MI and cerebral infarction are uncommon in young man without cardiovascular risk factors such as hypertension, diabetes, or dyslipidemia. The origin of myocardial infarction is usually either atherosclerotic stenosis or thromboembolic

events (TEEs) depending on the pre-existing cardiovascular risk factors. TEEs are more likely in our case presented without significant risk factors; which was confirmed in our case by coronary angiography.

Lactate dehydrogenase (LDH) was elevated and it has been demonstrated in one study that the elevated lactate dehydrogenase (LDH) is associated with thromboembolic events [7].

The proposed mechanisms of these events after receiving chemotherapy are direct endovascular damage, decreased activity of anticoagulant protein C, elevated plasma Von-willberand factor level and hypomagnesemia [5] however, no disorders of the coagulation system have been identified in our case, magnesium serum level was normal, and no measured decrease in protein C and S. We could not find any evidence of cumulative dose of chemotherapy is related to the incidence of thromboembolic events.

Vascular spasm may contribute or exaggerate thromboembolic events in smokers where nicotine may play a role in vascular effects as it may worsen vasospasm. The optimum confirmatory method of the causative drug is re-challenging the case with the offending agent but the ethical consideration is an issue so the team recommended changing the regimen with less toxic medication.

There are very few reported cases of combination of cerebral infarction and myocardial infarction. A large prospective clinical trial is needed to assess the actual incidence of thromboembolic events and how to prevent the occurrence in cancer patients receiving different regimens of chemotherapy.

4. CONCLUSION

Thromboembolic events are adverse events associated with chemotherapy treatment that may need further attention in regard to the initial prevention including pharmacological prophylaxis and possibility of an alternative regimen particularly in patients with testicular germ cell tumor.

A routine cardiology consultation before initiating cardio-toxic chemotherapy is highly recommended, especially when using cisplatin-based chemotherapy for solid tumors. Further investigations are highly recommended before starting chemotherapy especially in patients at

high risk including using stress tests or a computerized tomography (CT) coronary angiogram. In addition to this; the patient should be counseled about the signs of acute coronary syndromes to seek immediately for medical advice if happened.

CONSENT

It is not applicable.

ETHICAL APPROVAL

It is not applicable.

COMPETING INTERESTS

Authors have declared that no competing interests exist.

REFERENCES

1. Jemal A, Siegel R, Xu J, Ward E. Cancer statistics, 2010. *CA Cancer J Clin.* 2010; 60(5):277-300. DOI: 10.3322/caac.20073. Epub 2010 Jul 7.
2. Garcia-del-Muro X, Maroto P, Guma` J, Sastre J, Lo´pez Brea M, Arranz JA, et al. Chemotherapy as an alternative to radiotherapy in the treatment of stage IIA and IIB testicular seminoma: A Spanish germ cell cancer group study. *J Clin Oncol.* 2008;26:5416-5421. DOI: 10.1200/JCO.2007.15.9103. Epub 2008 Oct 20.
3. Grenader T, Shavit L, Ospovat I, Gutfeld O, Peretz T. Aortic occlusion in patients treated with Cisplatin-based chemotherapy. *MT Sinai J Med.* 2006; 73(5):810-812.
4. Numico G, Garrone O, Dongiovanni V, Silvestris N, Colantoniol, Di Costanzo G, et al. Prospective evaluation of major vascular events in patients with nonsmall cell lung carcinoma treated with cisplatin and gemcitabine. *Cancer.* 2005;103(5): 994-9. Comment in: *Cancer.* 2005;104(5): 1110-1111; author reply 1111.
5. Ohashi S, Yazumi S, Nishio A, Fukui T, Asada M, Chiba T. Acute cerebral infarction during combination chemotherapy with s-1 and cisplatin for a young patient with a mucinproducing adenocarcinoma of the stomach. *Intern Med.* 2006;45(18):1049-1053.

6. Weijl NI, Rutten MF, Zwinderman AH, Keizer HJ, Nooy MA, Rosendaal FR, et al. Thromboembolic events during chemotherapy for germ cell cancer: A cohort study and review of the literature. *J Clin Oncol.* 2000;18(10):2169-2178.
7. Piketty AC, Fléchon A, Laplanche A, Nouyrigat E, Droz JP, Théodore C. The risk of thrombo-embolic events is increased in patients with germ-cell tumours and can be predicted by serum lactate dehydrogenase and body surface area. *Br J Cancer.* 2005;93:909–914.
8. Sudhoff T, Enderle MD, Pahlke M, Petz C, Teschendorf C, Graeven U, et al. 5-Fluorouracil induces arterial vasoconstrictions. *Ann Oncol.* 2004;15(4):661-664.
9. Nuver J, Smit AJ, van der Meer J, van den Berg MP, van der Graaf WT, Meinardi MT, et al. Acute chemotherapy induced cardiovascular changes in patients with testicular cancer. *J Clin Oncol.* 2005; 23(36):9130-9137. Epub 2005 Nov 21. Comment in: *J Clin Oncol.* 2005;23(36):9051-9052. *J Clin Oncol.* 2006;24(21):3508; author reply 3508-3509. *J Clin Oncol.* 2006;24(15):2399; author reply 2399-2400.
10. Paiva CE, Michelin OC, Okoshi K. Acute coronary syndrome during chemotherapy: report of three cases. *Revista Brasileira de Cancerologia.* 2009;55(1):55-58.
11. Li SH, Chen WH, Tang Y, Rau KM, Chen YY, Huang TL, et al. Incidence of ischemic stroke post-chemotherapy: A retrospective review of 10,963 patients. *Clin Neurol Neurosurg.* 2006;108(2):150-156.
12. Dietrich J, Marienhagen J, Schalke B, Bogdahn U, Schlachetzki F. Vascular neurotoxicity following chemotherapy with cisplatin, ifosfamide and etoposide. *Ann Pharmacother.* 2004;38:242–246.
13. Brouha ME, Bloemendal HJ, Kappelle LJ, Winter JB. Cerebral infarction and myocardial infarction due to cisplatin-containing chemotherapy. [Article in Dutch]. *Ned Tijdschr Geneesk.* 2003; 147:457–460.
14. Karagoz B, Bilgi O, Akyol I, Ozgun A, Turken O, Kandemir EG. Cerebrovascular accident after chemotherapy for testicular cancer. *Mil Med.* 2009;174:320–321.
15. Jafri M, Protheroe A. Cisplatin-associated thrombosis. *Anticancer Drugs.* 2008;19: 927-929. DOI: 10.1097/CAD.0b013e3283100e9c
16. Seng S, Liu Z, Chiu SK, Proverbs-Singh T, Sonpavde G, Choueiri TK, et al. Risk of venous thromboembolism in patients with cancer treated with cisplatin: A systematic review and meta-analysis. *J Clin Oncol.* 2012;30(35):4416-4426. DOI: 10.1200/JCO.2012.42.4358. Epub 2012;13.
17. Moore RA, Adel N, Riedel E, Bhutani M, Feldman DR, Tabbara NE, et al. High incidence of thromboembolic events in patients treated with cisplatin-based chemotherapy: A large retrospective analysis. *J Clin Oncol.* 2011;29:3466-3473. DOI: 10.1200/JCO.2011.35.5669. Epub 2011 Aug 1.
18. Maiello M, Sharma RK, Ciccone MM, Reddy HK, Palmiero P. Early diagnosis of cardiac toxicity related to antineoplastic treatment. *Journal of Cancer Therapy.* 2011;2:161-166. DOI: 10.4236/jct.2011.22019.

© 2015 Mahfouz et al.; This is an Open Access article distributed under the terms of the Creative Commons Attribution License (<http://creativecommons.org/licenses/by/4.0>), which permits unrestricted use, distribution, and reproduction in any medium, provided the original work is properly cited.

Peer-review history:
The peer review history for this paper can be accessed here:
<http://sciencedomain.org/review-history/10607>